

Surg Neurol Int. 2011; 2: 107.

Published online 2011 Jul 30. doi: [10.4103/2152-7806.83391](https://doi.org/10.4103/2152-7806.83391)

PMCID: PMC3157093

# Immunoexcitotoxicity as a central mechanism in chronic traumatic encephalopathy—A unifying hypothesis

[Russell L. Blaylock](#)\* and [Joseph Maroon](#)<sup>1</sup>

Theoretical Neurosciences, LLC Visiting Professor of Biology, Belhaven University, Jackson, MS 315 Rolling Meadows Rd, Ridgeland, MS 39157, USA

<sup>1</sup>Department of Neurosurgery, Heindl Scholar in Neuroscience, University of Pittsburgh Medical Center, Team Neurosurgeon, The Pittsburgh Steelers, USA

Russell L. Blaylock: [ten.htuoslleb@7036yalB](mailto:ten.htuoslleb@7036yalB); Joseph Maroon: [ude.cmpu@cjnooram](mailto:ude.cmpu@cjnooram)

\*Corresponding author

Received 2011 Mar 23; Accepted 2011 Jun 6.

[Copyright](#) : © 2011 Blaylock RL.

This is an open-access article distributed under the terms of the Creative Commons Attribution License, which permits unrestricted use, distribution, and reproduction in any medium, provided the original author and source are credited.

## Abstract

Some individuals suffering from mild traumatic brain injuries, especially repetitive mild concussions, are thought to develop a slowly progressive encephalopathy characterized by a number of the neuropathological elements shared with various neurodegenerative diseases. A central pathological mechanism explaining the development of progressive neurodegeneration in this subset of individuals has not been elucidated. Yet, a large number of studies indicate that a process called immunoexcitotoxicity may be playing a central role in many neurodegenerative diseases including chronic traumatic encephalopathy (CTE). The term immunoexcitotoxicity was first coined by the lead author to explain the evolving pathological and neurodevelopmental changes in autism and the Gulf War Syndrome, but it can be applied to a number of neurodegenerative disorders. The interaction between immune receptors within the central nervous system (CNS) and excitatory glutamate receptors trigger a series of events, such as extensive reactive oxygen species/reactive nitrogen species generation, accumulation of lipid peroxidation products, and prostaglandin activation, which then leads to dendritic retraction, synaptic injury, damage to microtubules, and mitochondrial suppression. In this paper, we discuss the mechanism of immunoexcitotoxicity and its link to each of the pathophysiological

and neurochemical events previously described with CTE, with special emphasis on the observed accumulation of hyperphosphorylated tau.

**Keywords:** Cerebral concussion, chronic traumatic encephalopathy, cytokines, hyperphosphorylated tau, immunoexcitotoxicity, microglia, mild traumatic brain injury, quiniolinic acid

## INTRODUCTION

Approximately 1.5 million people in the United States annually experience a traumatic brain injury (TBI).[\[231\]](#) The number of unreported head injuries is much higher. Of these, a great number occur in sports-related events, professional and nonprofessional. There are approximately 100 000 to 300 000 concussions occurring in the game of football alone each year.[\[96\]](#) Most sports-related head injuries are minor concussions and a significant number are repeated injuries over a relatively short period of time. It is known that football players and boxers experience thousands of subconcussive blows during a career.[\[89,96\]](#)

Until recently, it was assumed that minor injuries resulted in few long-term neurological problems and were, in fact, characterized by a lack of neuropathological damage to the brain. Although it was recognized that a small percentage of these individuals could suffer from an array of neurological and constitutional complaints, called the post-concussion syndrome, there was little evidence of anatomical damage to explain these symptoms.[\[60,116\]](#)

Chronic changes in a number of participants in contact sports, including retired NFL football players, referred to as chronic traumatic encephalopathy (CTE), have been recently described. Many of these resemble some of the pathologic changes seen with Alzheimer's neurodegeneration (AD), including abundant widespread tau deposits, while some cases demonstrated no amyloid deposits and few neurofibrillary tangles (NFTs).[\[156,174,175\]](#) The hyperphosphorylated tau seen in CTE is identical to that associated with AD.[\[156\]](#) Subsequent studies have demonstrated two basic patterns of chronic pathology in CTE, one with abundant diffuse amyloid plaques and hyperphosphorylated Tau and another essentially devoid of amyloid plaque, but having abundant tau.[\[156\]](#) Approximately 50% of CTE patients lack significant amyloid plaque accumulation. The presence of apolipoprotein E (APOE) genotypes, in particular APOE4 allele, or other unique constitutional patterns may explain the difference in the two pathological presentations.[\[115\]](#) The APOE4 allele, especially if homozygous, significantly increases one's risk of late-onset AD. The age of onset can also play a role in the presence of inclusion bodies.

The etiology of these changes to date has not been explained by a defined central mechanism that would explain the prolonged progression of neurodegenerative changes seen in this syndrome. We are of the opinion that there exists abundant evidence that mild, repetitive concussions can trigger a process called immunoexcitotoxicity that in some cases can result in a progressive degeneration in a pattern seen with CTE. A number of studies have shown immune proinflammatory cytokine responses in the traumatized brain that are widespread, with more intense localization within areas of the brain also affected in Alzheimer's disease. [\[110,134,156\]](#) Most such studies have examined acute immune effects in moderate to severe TBI, but a few are

concerned with chronic immune responses as well. [70,79,84,98,208,211] Likewise, there are a number of studies, both in human beings and experimental animals, demonstrating a massive acute accumulation of glutamate, aspartate, and other excitotoxins in the central nervous system (CNS) following TBI.[29,180,198,247]

## CLINICAL FEATURES OF CHRONIC TRAUMATIC ENCEPHALOPATHY

Martland in 1928 introduced the idea of a chronic progressive degeneration of the brain following repeated blows to the head in boxers, which he called the “punch drunk syndrome” and was later referred to as dementia pugilistica.[149] With the wider recognition of a similar chronic neurodegenerative disorder in a number of athletes and others exposed to repeated head injury, the term CTE was coined by Omalu *et al.* McKee, and others, subsequently have suggested that this syndrome may result from multiple cumulative subconcussive blows to the head.[156,174,175]

The presentation of the syndrome is rather insidious in its earliest stages, usually presenting with problems with recent memory, poor attention, bouts of disorientation, confusion, and frequent headaches. The rate of progression varies, but usually there is a progressive worsening of mental abilities. Poor insight and judgment, worsening of disorientation and confusion, and the onset of a number of antisocial behaviors are characteristic. A number of the symptoms can be related to poor prefrontal cortex executive function and limbic system dysfunction.

McKee *et al.* described clinical findings among football players with CTE as follows: Mood disorders (mainly depression); memory loss, paranoia, poor insight, or judgment (each found in 80%); outburst of anger, aggression, irritability, and apathy (each found in 60%); confusion, reduced concentration, and agitation (each found in 40%).[156]

In severe cases, they found a progressive slowing of motor movements, a staggering, propulsive gait, masked faces, impaired speech, tremors, vertigo, and deafness. A number of patients with brainstem-related neurological deficits also develop dysarthria, dysphagia, and ocular abnormalities. Clinically, one sees not only a progressive neurological deterioration, but also widespread involvement of the brain and spinal cord. A major difference between AD and CTE is the anatomical distribution of the pathological changes. With CTE, one sees much wider CNS involvement and patchy cortical distribution of the lesions that mostly involve the superficial cortical layers.

Of the 51 cases of CTE examined neuropathologically by McKee *et al.*, 46 (90%) were athletes, the majority of which were boxers (85%).[156] The football players (11%) had a playing time varying from 14 to 23 years. One-third were symptomatic at the time of their retirement from the sport and half were symptomatic within 4 years of stopping play. In most of the cases, there was a slow progressive decline lasting decades. They reported motor symptoms in 42% of subjects, mainly those related to Parkinsonism.

It is interesting to note that of their football players, all died relatively young, from 36 to 50 years, and had a more rapid progression of symptoms than the boxers. There seemed to be a discrepancy between the official reported concussions and those reported by the family. Although most did not report taking performance-enhancing drugs or illicit drugs, one is not always sure how accurate these are reported. Alcohol use was frequent among retired athletes. Suicides and even homicides have been reported with increased frequency with CTE. Which came first, the depression, addiction, and/or suicide tendency or the CTE is not always easy to determine, but these studies seem to indicate that the neuropsychiatric syndromes followed the course of the CTE.

## **PATHOLOGICAL FEATURES OF CHRONIC TRAUMATIC ENCEPHALOPATHY**

Descriptions of the gross pathology of boxers with dementia pugilistica describe reduced brain weight, enlargement of the lateral and third ventricles, fenestrated cavum septum pellucidum, and scarring and neuronal loss in the cerebellar tonsils.[\[52\]](#) Brain atrophy was greatest in the frontal lobe (36%), temporal lobe (31%), and parietal lobe (22%), with the occipital lobe being rarely involved. It is interesting to note that the greatest atrophy occurred in the entorhinal cortex, hippocampus, and amygdala and appeared as a late event. These are the most involved areas of the AD brain as well and contain abundant glutamate receptors as well as cytokine receptors.[\[3,201\]](#) They also described pallor in the substantia nigra and locus ceruleus, areas markedly affected in Parkinson's disease (PD) and AD, respectively.[\[27\]](#)

McKee *et al.* also noted marked atrophy of the entorhinal cortex, hippocampus, and amygdala in a number of their cases, which was accompanied by very dense gliosis and neurofibrillary degeneration.[\[156\]](#) With advanced disease, they observed severe neuronal loss in the subcallosal and insular cortex, as well as mammillary bodies, medial thalamus, substantia nigra, locus ceruleus, and nucleus accumbens.

They noted that NFTs, astrocytic tangles, and dot-like spindle-shaped neuropil neurites (NNs), indicating severe neuronal injury and degenerating neurons, were commonly seen in the dorsolateral frontal, subcallosal, insular, temporal, dorsolateral parietal, and inferior occipital cortices. There was a consistent appearance of perivascular tau-immunoreactive particles irregularly distributed in the cortex, primarily in the superficial layers.

They also found involvement of the white matter, which was less severe than the cortex. NNs and fibrillar astrocytic tangles were found in the corpus callosum and subcortical white matter, especially the U-shaped fibers. Dense NFTs, ghost tangles, and astrocytic tangles were seen in the olfactory bulbs, hippocampus, entorhinal cortex, and amygdala. These inclusions were noted to be much denser than those found in AD. The widespread distribution of the NFTs and astrocytic tangles is in keeping with the rotational/acceleration-deceleration injuries seen with head injuries in sports. Significant involvement was seen throughout the brain stem, involving several cranial nerve nuclei. Interestingly, the NFT were commonly seen at the sulcal depths.

As with AD, dense NFTs were seen along the medial temporal lobe and within CA1 and subiculum. Extremely dense NFTs with ghost tangles and severe neuronal loss were seen in entorhinal cortex, hippocampus, and amygdala (case 3). Again, the abnormal tau proteins were indistinguishable from NFTs in AD and were composed of all six brain tau isoforms. The anatomic distribution of the NFTs did differ from AD, which would be expected since AD is a spontaneous disorder and CTE is secondary to repeated diffuse brain injury.

Of the 51 cases examined by McKee *et al.*, diffuse plaques were found in 22 (44%), neuritic plaques in 13 (27%), and amyloid angiopathy in 3 (6%).[\[156\]](#) There was a significant discrepancy from previous reports in that others described abundant A $\beta$  deposits in most cases of CTE and McKee *et al.* found none.[\[156,234,240\]](#) Uryu K and co-workers found extensive  $\alpha$ -synuclein accumulation in axons associated with acute brain trauma, but McKee found no  $\alpha$ -synuclein immunostaining in any of their 51 CTE cases.[\[240\]](#)

## EXCITOTOXICITY

Glutamate is the most abundant neurotransmitter in the brain, being utilized in 50% of the synapses in the CNS overall and 90% in the cortex; yet, it is often ignored when discussing the chronic degenerative effects of TBI.

In 1969, Dr. John Olney described a reaction that occurs when neurons are exposed to excess glutamate extracellularly, which he named excitotoxicity.[\[173\]](#) In his initial study, specific damage to a number of brain structures were demonstrated using rats exposed to monosodium glutamate. In his original description, when neurons were exposed to glutamate, there was a delayed reaction, which resulted in the death of neurons. Subsequent studies found that it was the uncontrolled entry of calcium into the neuron through glutamate receptor-controlled calcium channels that caused the excitatory response and that the calcium activated a number of death events by triggering cell death signaling pathways.[\[48,67,82\]](#)

Since this early discovery, a number of glutamate receptor types have been described, based on their activation by specific agonists, as well as a number of receptor subtypes. For a review on the physiology of glutamate receptors.[\[23,152\]](#)

Glutamate receptors are divided into ionotropic types, which include N-methyl D-aspartate (NMDA) and 2-amino-3-(5-methyl-3-oxo-1,2-oxazol-4-yl) propanoic acid (AMPA)/kainate receptors and metabotropic glutamate receptors. The latter are divided into three major groups, each with an assortment of eight cloned subtype receptors. The metabotropic glutamate receptors operate through G-protein membrane receptors and have varying responses to glutamate, both based on dose and physiology of the receptor.[\[36\]](#)

The ionotropic glutamate receptors regulate sodium and calcium channels. NMDA glutamate receptors can alter the intracellular concentration of calcium as calcium waves, which activate an assortment of cell signaling molecules utilized by the neuron to trigger various cellular events, including death signals as well as action potentials. Glutamate receptors make up the principle excitatory neurotransmitter, but share this excitatory response with cholinergic and purinergic receptors as well.

The principle sources of glutamate are from microglia and astrocytes.[225,258] It is utilized by neurons for neurotransmission. The excitotoxic cascade involves generation of high levels of reactive oxygen species/reactive nitrogen species (ROS/RNS), lipid peroxidation products (LPP), prostaglandins, and nitric oxide (NO) and can activate microglia.[36] Many of the pathological events described in traumatic brain injuries can also be seen with excitotoxicity—such as, increased amyloid processing, tau phosphorylation, microtubule disruption, membrane injury, dendritic retraction, synaptic loss, mitochondrial dysfunction, DNA injury, apoptosis, calcium dysregulation, and necrotic cell death.

Calcium dysregulation plays a major role in excitotoxicity. For example, Sun and co-workers, using a fluid concussion model for moderate TBI, found that calcium remained elevated in CA3 hippocampal neurons for 30 days and never returned to baseline levels.[225] The calcium elevation was not secondary to cell death, but was shown to result from overactivation of NMDA and AMPA receptors by glutamate. Sun suggested that calcium dysregulation seen with moderate TBI might be permanent.

Normally, AMPA receptors are calcium impermeable, but under conditions of trauma, hypoxia/ischemia, and in neurodegenerative diseases, there is a switch to Glu2-lacking AMPA receptors that are calcium permeable.[25,251] Mild frontal TBI has been shown to cause a rapid switching to calcium-permeable AMPA type receptors within cerebellar Purkinje cells, which normally lack functional NMDA receptors. [13]

Obrenovich and Urenjak suggested that excitotoxic mechanisms are often treated simplistically and that a more realistic concept would involve a number of states that could increase glutamate excitotoxicity without dramatic elevations in glutamate levels.[171] These conditions include increased density of glutamate receptors (as with NMDA and AMPA receptor trafficking); altered ionic selectivity of ionotropic receptors; abnormalities in receptor sensitivity and modulation; and enhancement of glutamate-mediated synaptic efficiency.

There is growing evidence that there is a synergistic interaction between the glutamate receptors and certain cytokines that can dramatically increase neuronal injury and may precipitate chronic neurodegeneration.[76] The lead author has coined the term immunoexcitotoxicity to describe this mechanism.[43,44]

## **AXONAL INJURY WITH REPETITIVE MILD TRAUMATIC BRAIN INJURIES**

A number of early studies indicated that acceleration/deceleration and rotational injuries to the head could produce diffuse damage to axons as well as injury to cortical and subcortical neurons.[1,2] One of the most commonly described pathological findings in the traumatized brain was diffuse axonal injury. More recent studies have shown that the injury to the axons was not diffuse, but rather affected specific white matter tracts based on the severity of the injury.[160] Interestingly, it has been shown that with mild injury, most of the initial damage to the axons was not anatomical shearing, but rather involved a progressive degenerative process



with any severing of the axons occurring as a secondary event.[33] That is, most of the axonal damage was neurodegenerative and not mechanical.

A number of pathophysiological events can occur with TBI, including disruption of the blood-brain barrier (BBB), cerebrovascular reactivity changes, hypoxia/ischemia, edema, mitochondrial disruption, neurochemical changes in the membranes, and changes in the brain's electrical activity.[76,199] [Figure 1]. Studies have also shown prolonged accumulation of ROS and RNS, LPPs, glutamate accumulation, and evidence of progressive inflammation.[12,102,210,238,247]

Both myelin and axons possess a number of glutamate receptor types, with AMPA/kainate receptors being the most abundant.[224,228,237] Although no one has examined excitotoxic progressive neurodegeneration of axons with brain trauma in detail, studies of axon neurodegeneration in other disorders suggest that immunoexcitotoxicity is playing a major role. Oligodendroglial cells also contain glutamate receptors and can undergo excitotoxic degeneration when extraneuronal glutamate levels are sufficiently elevated.[61] The presence of inflammation has also been shown to enhance excitotoxic injury to axons.[166,197]

## ROLE OF MICROGLIA

More recent studies have pinpointed the activation of the brain's microglia as an early and primary event in traumatic brain injuries and that there is an interaction between proinflammatory immune cytokine receptors and glutamate receptors[15,42,57,69,72,75,79,103,107,113,221] [Figure 2].

Although all cell types, neurons, astrocytes, oligodendroglia, endothelial, and microglia can release proinflammatory cytokines, the major resident immune cells of the brain are the microglia. Microglia are thought to arise from macrophage/monocytes from the bone marrow during embryogenesis and later during brain inflammatory responses. Peripheral macrophages can also infiltrate the brain and transform into microglia in response to a disturbance to its homeostasis.[9,68]

Microglia, when activated, can secrete a number of anti- and proinflammatory cytokines, chemokines, NO, prostaglandins, trophic factors, free radicals, LPPs, and three forms of excitotoxins-glutamate, aspartate, and quinolinic acid (QUIN).[9,22,190] In an inactivated state, called ramified, they exhibit continuous localized motility of membrane extensions and secrete a number of trophic molecules, such as brain-derived neurotrophic factor (bDNF), neurotrophic factor (NTF), and bFNF. Microglial membranes contain receptors for cytokines, chemokines, receptor for advanced glycation end products, complement, thrombin, RANTES (Regulated upon Activation, normal T-cell Expressed and Secreted), AMPA/kainate, metabotropic glutamate receptors, cholinergic, and P2 receptors, thus reacting to a great number of interstitial signals.

It has been shown that resident brain microglia react rapidly to disturbances in homeostasis and that their response to activation can vary considerably.[139] It has been proposed that there are three basic states of microglial activation: neurotrophic/phagocytic, predominately neurodestructive, and intermediate, each responding to a different set of membrane signals, which can be time and cytokine dose dependent.[28]

Studies have shown that proinflammatory cytokines can activate a release of excitotoxins from microglia and astrocytes and that excitotoxins can likewise activate the release of immune proinflammatory cytokines from these same cells.[[27,42,191,256](#)] It is important to appreciate that exposure to individual proinflammatory cytokines are not neurodestructive, but that in certain combinations, such as IL-1 and tumor necrosis factor-alpha (TNF-alpha), destructive reactions can be robust.[[114,118](#)] The evidence strongly suggest that it is the combination of proinflammatory cytokines and excitotoxins that lead to neurodegeneration, rather than inflammation alone. Subtoxic concentrations of glutamate, when combined with subtoxic concentrations of lipopolysaccharide (LPS) or proinflammatory cytokines, become fully neurotoxic.[[78](#)]

Because both proinflammatory cytokines and excitotoxin release occur simultaneously, one would expect to see a synergistic neurodestructive cascade set in motion [[Figure 3](#)]. A number of studies have confirmed this destructive interaction.[[7,104](#)] This synergism between the immune system and excitotoxic levels of glutamate, aspartate, and QUIN also have similar effects on the BBB, brain vasculature, development of edema, and metabolic changes seen with TBI.[[16,85,108,122,206,217](#)]

## **THE IMMUNOEXCITOTOXICITY MECHANISM**

### **Basal resting state**

Both immune mediators and excitatory amino acids can be generated and secreted by activated microglia, astrocytes, and oligodendroglia. Although astrocytes are the main repository for glutamate and aspartate, activated microglia can release substantial amounts of these excitatory amino acids into the extraneuronal space.

Normally, the brain contains barely detectable levels of proinflammatory cytokines and at these levels several, such as interleukin-1beta (IL-1 $\beta$ ), interleukin-6 (IL-6), and TNF-alpha, act as neurotropic substances.[[59](#)] It has been shown that even very high levels of proinflammatory cytokines cannot damage neurons except in the presence of microglia.[[22](#)] Excitotoxins, also released by activated microglia, appear to be the most toxic component released by the microglia.[[6,85,108,122,206,217](#)]

### **Excitotoxicity**

In fact, compelling evidence suggests that proinflammatory cytokines may not kill neurons directly but do so by enhancing excitotoxicity. For example, Yawata and co-workers showed that LPS- or TNF-alpha-stimulated macrophages induce robust neurotoxicity, which was completely blocked by NMDA receptor antagonist MK-801 (dizoclipine).[[256](#)] A number of other studies demonstrate microglial and astrocytic glutamate as the neurotoxic factor in immune-mediated neurodegeneration.[[7,95,209](#)] The proinflammatory cytokines appear to be acting by enhancing excitotoxicity sensitivity.

### **Microglial activation**



It should be emphasized that microglial activation alone is not sufficient for neurodegeneration. Morimoto and co-workers, for example, demonstrated that injecting LPS into the hippocampus of rats alone produced substantial microglial activation but no significant evidence of neurodegeneration.[166] If ibotenate, an NMDA receptor agonist, was injected one day after the LPS, massive microglial activation occurred along with significant neurodegeneration, demonstrating that the most destructive component of immunoexcitotoxicity is the excitotoxicity component.

## **Mechanisms for microglia activation**

Recent studies have shown some of the mechanisms for this interaction of proinflammatory cytokines and glutamate receptors. For example, it has been shown that there is an enhancing destructive interaction between tumor necrosis factor receptor-1 (TNFR1) and AMPA receptors.[15,219] [Figure 4]. Activation of these particular TNF-alpha receptors increases the trafficking of AMPA receptors from the endoplasmic reticulum, so that more AMPA receptors are inserted on the synaptic membrane, thus making the synapse more sensitive to glutamate stimulation.

## **Neuronal destruction**

Neurons contain mostly the neurodestructive TNFR1 type receptors, whereas microglia contain the tumor necrosis factor receptor-2 (TNFR2) form, which is neuroprotective. This arrangement preserves the glia during brain inflammation. Low levels of TNF-alpha stimulate mainly neuroprotective TNFR2 and high levels stimulate the neurodestructive TNFR1.[15] Although no one has conducted studies to see if higher levels of TNF-alpha occur with repeated injury as opposed to an single impact, one would reasonably expect this.

## **Interleukin-1 Beta, TNF, and other agents as activators of microglia**

It has also been shown that IL-1 $\beta$  can enhance the sensitivity of the NMDA receptors and TNF-alpha can upregulate astrocytic glutaminase, the principle enzyme converting glutamine into glutamate.[179,226] [Figure 5]. Both of these cytokines can increase recruitment of microglia, which also increase brain inflammation as well as excitotoxicity.[232] It has also been shown that necrotic dying neurons enhance microglial-induced excitotoxicity by inducing glutaminase.[179]

IL-1 $\beta$  has been shown to be the main activator of microglia during brain disturbances and systemic IL-1 $\beta$  can cause CNS inflammation once it enters the brain, thus linking systemic inflammation and immune activation with worsening of brain pathology and pre-existing neurodegeneration.[22,55] There are other substances that can activate microglia, such as thrombin and interferon-(INF-gamma).[151,161] INF-gamma is one of the most potent stimulants for microglial activation.[14] Thrombin as a microglial activator would become more important with brain injuries involving contusions and more severe diffuse injury, where petechial or gross hemorrhages are involved.

## **Molecular actions of activated microglia**

Once activated in a neurodestructive or intermediate mode, the microglia would release large amounts of ROS/RNS, inflammatory prostaglandins, proteases, excitotoxins and recruit surrounding astrocytes to release their glutamate and aspartate. There is an intimate relation between microglia and astrocytes during brain inflammation. Astrocyte membranes contain receptors for virtually all of the neurotransmitters, chemokines, cytokines, and other immune mediators.[245] Astrocytes are the major source for glutamate, even though activated microglia can release neurotoxic concentrations as well.

## **Recruitment of macrophages to the CNS**

Release of chemokines, especially monocyte chemoattractant protein-1 (MCP-1) (also known as CCL2), stimulates the recruitment of peripheral monocytes/macrophages to the CNS. Entry into the CNS occurs at selected BBB sites and primarily the circumventricular organs (CVO), which have no BBB protection.[125,144,220] The main site of entry appears to be the choroids plexus, a major part of the CVO and the area postrema (dorsal vagal complex). A number of studies have shown that inflammatory stimulation of the vagus can activate brain microglia diffusely.[58,250]

With more severe injury to the brain, other leucocytes are recruited as well. There is evidence that recruitment of T-lymphocytes plays an important role in containing brain inflammation by interacting with activated microglia and that B-cell recruitment enhances brain inflammation.[35,158] Leukocyte recruitment is more intense with contusions than diffuse injuries.[252]

# **SEQUENTIAL MILD BRAIN INJURY, MICROGLIA PRIMING, AND PROGRESSIVE NEURODEGENERATION**

## **Priming of microglia**

Disturbances of brain homeostasis, including TBI, are known to prime and/or activate microglia and do so rather rapidly.[65,145] Of special importance to this proposed central mechanism is the concept of microglial priming. When microglia are stimulated initially, they can assume a primed state. Primed microglia are in an intermediate state between ramified (resting) and fully activated microglia and are characterized histologically by shortened processes and a rounder cell body. They also express cell surface markers similar to fully activated microglia, but do not release cytokines, chemokines, or other reactive molecules.[65] A number of conditions are known to prime microglia, including toxic environmental exposures, systemic immune stimulation, ischemia/hypoxia, brain aging, and brain trauma.[59,70,133,134,207]

## **Activation of microglia**

Once primed, subsequent stimulation, either by immune cytokines, chemokines, chemical toxins, or mechanical trauma, transforms the microglia into a fully activated state with a release of high levels of pro- and anti-inflammatory cytokines, chemokines, interferons, ROS/RNS, LPP, prostaglandins, and three excitotoxins-glutamate, aspartate, and QUIN.[[51](#),[55](#),[200](#)] Priming causes these activated microglia to become hyper-reactive, releasing much higher concentrations of inflammatory cytokines and excitotoxins than are normally released.[[55](#)] [[Figure 6](#)]. This can produce significantly greater injury to surrounding neurons, dendrites, and synaptic connections than would occur in the absence of pre-existing microglial priming.

## **Chronically primed microglia**

There is growing evidence that priming can exist for prolonged periods.[[18](#),[125](#),[145](#),[148](#),[204](#)] Normal homeostatic innate immune mechanisms allow the brain's neurodestructive microglial activation to shut down once the danger has been contained; for example, killing of invading microorganisms. Switching of neurodestructive microglial activation to a neuroreparative mode allows the microglia to repair whatever bystander damage has been done during the neurodestructive mode of activation. This includes the release of neurotrophic molecules, including BDNF, NTF, and basic fibroblast growth factor. It has been proposed that with chronic microglial neurodegeneration, this switching process does not occur, leading to progressive and prolonged neuronal injury.[[125](#)]

## **Reversal priming/activation of microglia**

Switching of the microglia is not completely understood but involves interactions with interleukin-10 (IL-10), interleukin-4 (IL-4), interleukin-13, CD200 (cluster of differentiation 200), and fractalkines, all of which reduce microglial activation and downregulate the release of proinflammatory cytokines.[[140](#),[141](#)] [[Figure 7](#)]. Microglia from mice lacking CD200 receptors, for example, demonstrate exaggerated proinflammatory cytokine release with LPS stimulation. CD200 deficiencies have been reported with surgical brain trauma in aged rats.[[38](#)]

## **How primed microglia function in repeated head injury**

When the microglia remain primed, a second concussion, even a mild concussion, would be expected to trigger a second round of hyperactive neurodestructive microglial activation. With each successive concussion, the process would be repeated. It is not clear whether the neurodestructive mode of the microglia remain fully activated during the process of prolonged neurodegeneration, or if one is witnessing repeated episodes of the priming effect. This would explain the observation that repeated mild brain trauma results in a higher incidence of prolonged neurological injury than a single injury, even when separated by many months.[[64](#),[143](#),[153](#)] Although accumulative damage may account for some of the effects of repeated trauma, it would not account for the progressive neurodegeneration seen long after the last traumatic episode; however, this hypothesis offers an explanation for the progressive nature of this disorder.

The difference in the anatomical distribution of the pathological changes as compared with other spontaneous neurodegenerative dementing disorders, as well as the greater constellation of symptoms, would be explained by the diffuse nature of brain injury seen with closed head injuries. It is known that the hippocampus, entorhinal cortex, and amygdala are more prone to immunoexcitotoxic injury than would be other parts of the brain, again explaining the intense damage seen in these anatomical areas in CTE cases.[200] The progressive neurodegeneration triggered by the immunoexcitotoxicity would be expected to occur in areas of the brain receiving the greatest amount of damage with each concussive episode and areas with the high microglial concentration.

### **Other events and toxins that enhance microglia activation**

In a real world situation, these individuals would also be exposed to a number of other neurologically damaging events and exposures to neurotoxins that would worsen and accelerate the process. It is known that a number of pesticides/herbicides and fungicides can activate microglia chronically[145,146] These chemicals are ubiquitous in our environment and tend to accumulate in the brain because of its high lipid content. A number of commonly encountered neurotoxic metals, especially aluminum and mercury, have also been shown to activate microglia chronically.[37,43] Because many accumulate within the brain and can remain for a lifetime, they can become major triggers for both priming and chronic microglial activation. Interestingly, systemic immune activation has been shown to worsen neurodegeneration associated with some metals and pesticides.[78,164]

A number of studies have linked AD risk to latent viral infections in the brain. For example, the herpes simplex virus is strongly linked to AD risk.[66] It may be that those at greatest risk of CTE following repetitive trauma are those with a combination of such risk factors.

## **THE AGING BRAIN AND CHRONIC TRAUMATIC ENCEPHALOPATHY**

The progression of CTE neurodegeneration accelerates with aging of the individual. Since aging itself primes microglia, one would expect such a picture.[200] Aging is also associated with a number of conditions that would accelerate neurodegeneration, such as mitochondrial dysfunction, loss of membrane fluidity, microglial and astrocytic dystrophy, accumulative effects of systemic infections, impaired antioxidant repair systems, impaired autophagy, endoplasmic reticulum (ER) stress, accumulation of DNA damage, and impaired DNA repair mechanisms.[65]

There are a compelling number of studies showing that with aging, one sees an increase in the number of primed and activated microglia, accompanied by higher levels of brain proinflammatory cytokines.[172,207,246] Priming of microglia has been described in a number of neurodegenerative conditions, including Alzheimer's disease.[207]

Several studies have described increased levels of inflammatory mediators, both in the brain and systemically, in cases of AD.[71,172,207,246] Most telling is the appearance of activated

microglia in mild cognitive impairment (MCI), considered an early stage in dementia for a number of individuals.[71] This study found that the MCI patients with the highest risk of developing dementia also has the highest IL-1 levels. A previous study found a strong link between elevated soluble TNFR1 and TNFR2 in the CSF and plasma and the risk of MCI patients developing dementia.[32]

Likewise, a number of studies have shown a poorer outcome in aged individuals and aged neurological trauma models following TBI as compared with younger subjects.[11,83,205,235] Of special importance is the balance of proinflammatory and anti-inflammatory cytokines, such as IL-10, IL-4, and transforming growth factor- $\beta$ 1 (TGF- $\beta$ 1). With aging, and more so with neurodegenerative disorders such as Alzheimer's disease, one sees lower levels of IL-10 and TGF- $\beta$ 1 than found in younger brains.[133,249,257] In animals, low IL-10 levels have an associated impairment of learning and memory.[249]

Streit and co-workers reported that with aging, microglia become more dysfunctional and this may interfere with normal mechanisms that are designed to terminate immune activation by activating anti-inflammatory protection normally seen with the reparative phenotype of microglia.[223]

Recent evidence demonstrates reduced CD200 and CD200 microglial receptors in pathologically affected areas of the Alzheimer's brain.[248] Macrophages from PD patients have also shown reduced CD200 receptors.[138] Reductions in CD200 have also been reported with aging in rats.[140] Since CD200 receptors on microglia are considered major players in microglial switching from a neurodestructive mode to a neuroreparative mode, this could explain prolonged priming/activation of microglia in neurodegenerative disorders [Figure 8].

## **IMMUNOEXCITOTOXICITY IN THE ACUTELY CONCUSSED BRAIN**

### **Pathophysiology of the acute concussed brain**

#### **Microglia**

Acceleration/deceleration and rotational injuries have been shown to trigger rapid intrinsic induction of immune factors, including pro- and anti-inflammatory cytokines, chemokines, interferons, NO, prostaglandins, and a number of trophic molecules.[6,47,79,99,106,165,202,230] Some studies indicate that this reaction can occur within 1 hour of impact and may continue for a prolonged period. In uncomplicated minor single concussions, the glutamate is removed by intrinsic brain mechanisms, primarily through glutamate transport proteins, within 24 to 72 hours.[242,258] The same is true for the release of immune factors, with somewhat longer retention, even up to a month following injury.[123,195,214]

Immediately upon impact, neuroanatomic structures are stressed, with microscopic injury to cell membranes, axon sheaths, synapses, and dendrites that will not be detectable on most imaging

studies and may not be evident on light microscopy. These mechanical forces have been shown to rapidly activate resident microglia in the areas of stress and eventually at some distance to the major stress points.[[134,222](#)]

There is some evidence that resident microglia are mainly phagocytic and secrete trophic factors needed in early brain repair and neuroprotection. It appears that it is the invading macrophages, which are transformed into activated microglia, that act as antigen-presenting cells and secrete most of the destructive factors associated with neurodegenerative responses. A number of monocytes/macrophage attracting chemokines, such as macrophage inflammatory protein-1 and MCP-1, are released with impact head injuries.[[189,192](#)]

### **Cerebrovascular reactions**

Cerebrovascular reactions to minor TBI are less than that occurring with moderate or severe injuries, but even minor injuries can result in alterations in autoregulation of the vasculature and this can lead to ischemia/hypoxia.[[252](#)] Glass and co-workers demonstrated that mechanical injury to primary mixed neuronal cultures followed by hypoxia significantly enhanced neuronal injury and that blocking NMDA receptors and/or AMPA/kainate receptors after hypoxia induction dramatically attenuated neuron loss.[[81](#)] Blocking either type of glutamate receptor alone had less of an effect.

### **Lipid peroxidation**

Although massive release of ROS/RNS and LPPs occurs with moderate and severe brain impact injuries, there is evidence that lesser accumulations occur in minor head injuries.[[210](#)] Both proinflammatory cytokines and excitotoxins can dramatically increase brain ROS/RNS generation and would expect to be more intense when occurring together. There is also evidence that oxidative stress enhances TNF-alpha neurotoxicity and that antioxidants reduce this toxicity.[[238](#)]

### **Nitric oxide**

Elevations in NO with brain injury are also known to occur.[[46,77,262](#)] A number of studies have shown that NO itself is neuroprotective, but in the face of high free radical generation, NO combines with superoxide to form the very destructive peroxynitrite radical, which has a specific damaging effect on mitochondrial function.[[212](#)] NO also competes with oxygen for cytochrome oxidase within mitochondria, reducing ATP generation and triggering glutamate release.[[26](#)] Bal-Price and Brown have shown that NO killing of neurons was completely prevented by blocking glutamate receptors.[[7](#)] Reducing mitochondrial energy production has been shown to greatly increase the neurodestructive effects of excitotoxins.[[88,168,169](#)] The metabotropic glutamate receptors play a significant role in this process, since they can either enhance excitotoxicity or reduce it, depending on the specific subtype of metabotropic receptors activated or suppressed.[[170](#)]



## Mechanisms of brain protection

Of significant importance is the role played by the protective mechanisms utilized by the brain to contain excess extraneuronal excitatory amino acids. Because these neurotransmitters are so destructive when elevated extraneuronally, the brain has a number of mechanisms to restore glutamate homeostasis. These include glutamate transporter proteins, the cystine/glutamate antiporter system, glutamine synthetase, glutamic acid decarboxylase, and glutamic acid dehydrogenase.

Of prime importance are the glutamate transport proteins, EAAT (excitatory amino acid transporter) 1-5, with the first two also named GLAST (glutamate-aspartate transporter [also known as EAAT-1]) and glutamate transporter-1 (GLT-1, also known as EAAT-2), respectively. Both microglia and astrocytes utilize these transporters. Of particular importance is that these transporters are redox sensitive and in conditions of high free radical and LPO generation, one can see severe suppression of glutamate transport into microglia and astrocytes.[126,131] It is also known that under specific conditions, such as oxidative stress, one can see reverse glutamate transport so that glutamate moves from the astrocytes into the extraneuronal space, thus worsening excitotoxicity.[8,86] The LPP, 4-hydroxynonenal, has been shown to powerfully suppress glutamate transport proteins.[19] Elevations of 4-hydroxynonenal are commonly seen in all of the neurodegenerative diseases, strokes, hypoxia/ischemia, and with brain trauma.[19,135,157,261]

The cystine/glutamate  $X_c$  antiporter is an exchange system where intracellular glutamate is exchanged for extracellular cystine, so as to supply cysteine for glutathione (GSH) generation.[147] Excess extracellular glutamate prevents exchange and lowers astrocytic GSH. The astrocyte is the major source of neuronal GSH. Under such conditions, the neuron becomes highly vulnerable to conditions of oxidative stress, as seen with concussive brain injuries and immunoexcitotoxicity.

## CHRONIC TRAUMATIC ENCEPHALOPATHY AND WHITE MATTER DEGENERATION

There is growing evidence that AD, autism, and other dementing disorders involve connectivity problems secondary to white matter injury.[48,218] Although most pathological studies, both clinical and experimental, are concerned with severe TBI, some relate to minor injury. DTI (diffusion tensor imaging) studies have demonstrated occult white matter injury in cases of mild TBI (mTBI) not seen with typical magnetic resonance imaging (MRI) scanning techniques.[109] Experimental studies have shown a progressive loss of axon integrity following TBI. For example, Rodriguez-Paez *et al.*, using a moderate parasagittal fluid-percussion injury model, found chronic axonal changes accumulating as late as 6 months after injury.[195] They examined the fimbria, external capsule, thalamus, and cerebral cortex, ipsilateral to the injury, using electron microscopy (EM) and light microscopy and found a progressive loss of axons over time with significant macrophage/microglial infiltration as late as 6 months postinjury.

## **Diffuse Axonal Injury with Traumatic Brain Injury**

Kraus *et al.* found, using DTI studies, that the white matter load index was strongly correlated with cognitive function.[121] Kumar *et al.* tracked serial changes in white matter using DTI scanning in moderate TBI and found that fractional anisotropy (FA) and mean diffusivity (MD) in the genu of the corpus callosum appear early and persisted at 6 months as a secondary injury with microgliosis.[123] Inglese *et al.* examined 46 patients with mTBI and 29 healthy volunteers utilizing MRI and DTI imaging and found significant abnormalities (FA) in the corpus callosum, internal capsule, and centrum semiovale and increases in MD in the corpus callosum and internal capsule.[109]

The question to be answered would be—does repetitive brain injury trigger a chronic immune and excitotoxic response that is prolonged and does this result in progressive states of neurodegeneration of axons?

A number of animal studies demonstrate a chronic degenerative process involving axons following TBI.[121,148] Iwata and co-workers, using a swine TBI model, found only limited axonal A $\beta$  accumulation within axons appearing acutely after injury, but did observe greater accumulation one month after injury that persisted for at least a year.[111] Chen *et al.*, also using a swine TBI model, found evidence of ongoing axonal pathology 6 months after rotational brain injuries.[45]

Human studies also demonstrate progressive white matter atrophy occurring after traumatic brain injuries.[17] Several studies have related this axonal injury to an accumulation of glutamate from activated microglia and astrocytes.[224,228,229] Studies have also shown that delayed axonal damage was worse in older animals, in keeping with previous observations of aging-related priming effects and immunoexcitotoxicity.[8] In older animals, one sees a greater release of glutamate secondary to reverse Na<sup>+</sup>-dependent glutamate transport from GLT-1 glutamate transporters. With aging, there is a dysfunction of GLT-1 glutamate transporters.[171]

### **Other neurological diseases**

Further evidence that glutamate excitotoxicity can cause delayed axonal transection comes from the studies of DeStefano and others in cases of progressive axonal transection in multiple sclerosis.[50,61,62,121,195] Interestingly, these areas of axonal transection occurred in regions unaffected by inflammation, most likely by glutamate excitotoxicity. Quardouz M and co-workers demonstrated pathological intra-axonal elevations of calcium triggered by stimulating AMPA/kainate receptors on axons, which they concluded could result in progressive axonal degeneration with white matter injury.[177,178]

## **SYSTEMIC IMMUNE STIMULATION AND PROGRESSIVE NEURODEGENERATION**

The demonstration of diffuse, intense deposits of hyperphosphorylated tau in the brains of retired NFL players who had sustained a number of concussions during their years of active play

refocused attention on the possible link between repetitive concussions and Alzheimer's-like dementia. Dementia pugilistica among professional boxers and reports of neurodegenerative changes in the brains of others engaged in contact sports have been reported sporadically in the medical literature.

As stated, several studies have shown that repetitive injuries are more damaging than single concussion of the same severity, even when separated by several months.[\[45,111\]](#)

It is also known that systemic immune activation can worsen existing brain pathology by a similar mechanism, that is, by stimulating already primed microglia.[\[56,58,59\]](#) In a real world situation, these players would be exposed to recurrent infections, and other systemic immune activating events, that would add to existing brain immune activation. Stress, for example, has been shown to increase brain microglial priming and activation, as well as increased brain ROS/RNS and lipid peroxidation (LPO).[\[5,30\]](#)

### **Systemic influences on brain microglia**

Systemic immune stimulation has been shown to activate microglia within the brain, yet even intense systemic immune stimulation does not lead to neurodegeneration, unless there exists preexisting brain pathology.[\[4,51\]](#) Alterations in brain function, such as fatigue, sleep disturbances, cognitive dysfunction, anxiety, and depression, associated with systemic immune stimulation, is known as sickness behavior. Studies have shown that delayed symptoms, especially depression and cognitive dysfunction, resemble human disorders previously not thought to be related to immune stimulation of the brain.[\[57,58\]](#) More recent studies have also linked these behaviors and cognitive impairments to excess excitatory amino acids in specific brain areas.[\[155,163,181\]](#)

### **Brain pathology is necessary for immunoexcitotoxicity**

Combrinick *et al.* demonstrated the effect of systemic immune stimulation on priming by preexisting brain pathology in a study in which he injected ME7-induced murine prion disease protein into the brain and then stimulated the systemic immune system with LPS.[\[51\]](#) They demonstrated much higher levels of IL-1 $\beta$  in the ME7 brain as compared with LPS injected without the ME7 priming. This would also explain the observation of accelerated progression of Alzheimer's disease and the worsening of neurological TBI outcomes in those having systemic infections.[\[185,241\]](#) Sudden onset of reversible dementia has also been described in elderly patients following systemic infections. It is accepted that during the pre-clinical phase and early stages of AD, most of the damage is secondary to dendritic and synaptic injury, and that this has the potential for repair. With more advanced stages, neurons are lost in increasing numbers and reversal is less likely. Lemstra *et al.* examined 13 patients having systemic infections without CNS infections as compared with 17 age-matched noninfected controls and demonstrated widespread microglial activation in the grey matter of the former.[\[128\]](#)

It has been shown that proinflammatory immune stimulation by itself is insufficient to cause brain pathology, but pre-existing or coexisting brain pathology, in the form of excitotoxicity, can trigger extensive neurodegeneration. For example, Morimoto *et al.* found that coinjection of LPS

plus ibotenate, an NMDA receptor agonist, led to significant neuronal degeneration and severe tissue collapse, but that blocking excitotoxicity prevented any tissue damage, despite substantial microglial activation.[166] If the ibotenate was given 1 day after the LPS injection, gross microglial activation occurred along with significant neurodegeneration.

With repeated minor brain injury, after the first injury, one would expect to see microglial priming, some degree of axonal and synaptic injury, and alteration in calcium homeostasis, which could act as the catalyst needed for the neuronal destruction seen in this study.

## **The aging brain and systemic influences on microglia**

It has been shown in human beings and experimental animals that sickness behavior is more intense and lasts longer in the aged.[10,216] This is, in part, because they already have primed microglia. The major stimulus for microglial activation, both systemically and from within the brain itself, is from IL-1 $\beta$ , even though other cytokines and chemokines can stimulate activation and recruitment. Studies have shown that IL-1 $\beta$  and LPS given systemically can produce widespread microglial activation in the brain.[64,150] They also activate a number of genes concerned with inflammation and free radical generation.

Cytokine receptors exist heterogeneously in the adult brain, with high concentrations in the hippocampus and limbic system.[52] IL-1 $\beta$ , IL-6, and TNF-alpha have been shown to impair learning and memory in both human beings and experimental animals.[34,215,244] The use of cytokines, interferons, and other immune mediators in human beings to treat viral hepatitis and cancer have demonstrated an increased incidence of depression, speech difficulties, and cognitive impairment in a large percentage.[76,129]

## **Traumatic brain injury and neurodegeneration**

In the case of repetitive TBI, the first injury will prime the microglia and this priming state may last for very prolonged periods in some cases.[73,145,167] The second injury initiates a hyper-response from the activated microglia, with an outpouring of proinflammatory immune cytokines and excitotoxins [Figure 9]. With each injury, the response may increase the likelihood that the proinflammatory/excitotoxic microglial mode will be prolonged. It has been shown in experimental studies that IL-1 $\beta$  is released in the brain within one hour of impact and is elevated for 7 days postinjury and even longer in the aged brain.[137] Similarly, excitotoxins are also released from microglia and astrocytes on impact and can persist in the aged brain for prolonged periods.[40,120,255]

The presence of systemic immune activation from infections or any cause occurring throughout life has the potential to accelerate and enhance brain immunoexcitotoxicity. One must also consider other sources of systemic immune stimulation, including that from infectious illnesses, vaccinations, exposure to pesticides and industrial chemicals, and even stress. Stress has been shown to prime microglia and evoke microglial activation.[73]

Sandhir *et al.* conducted a controlled, moderate cortical impact injury (CCI) in mice, delivered to the sensorimotor area utilizing a dural impact method.[200] Sham-operated animals were used

for controls and had the same surgical procedure, without the impact. Tissues were harvested on day 1, 2, 3, 7, 14, and 28 post-impact. Examinations were done using real-time polymerase chain reaction (PCR) analysis of gene expression, immunoblotting of homogenized hippocampus, and immunohistochemical analysis of microglia and astrocyte activation utilizing staining with two microglial activation markers, CD11b (cluster of differentiation 11b [also called integrin alpha M]) and Iba1, and the astrocyte activation marker glial fibrillar acidic protein (GFAP).

They found that basal levels of both microglial activation markers were significantly higher in the aged hippocampus (age 21 to 24 months) than in the adult hippocampus (age 5 to 6 months). These markers increased after 24 hours following TBI and peaked at 3 days in both the adult and aged hippocampus, but was significantly higher in the aged hippocampus at all time points. Expression of Iba1 is a more sensitive and specific marker for microglial activation than CD11b and was 2-fold higher at 3 days and 3.5-fold higher at 7 days in the aged mice. Both of the microglial activation markers returned rapidly to basal levels by day 7 in the adult animals, but remained elevated at 14 days in the aged mice, suggesting prolonged neuroinflammation. Microglial activation was higher throughout the entire hippocampus in both the adult and aged hippocampus.

Two astrocytic activation markers were used, S100B (calcium binding protein B) and GFAP. Higher basal levels of both were seen in the aged mice brain as compared with the adult brains. Messenger RNA for both markers were elevated within 24 hours of CCI and peaked at day 7 in both. These markers rapidly returned to basal levels in the adult following injury, but remained significantly elevated at day 14 in the aged mice.

The highest microglial and astrocytic activation occurred in the dentate gyrus. Others have reported prolonged microglial activation in aged animals exposed to TBI, ischemia, and 1-methyl-4-phenyl-1,2,3,6-tetrahydropyridine (MPTP) toxicity.[[145](#),[185](#),[215](#)] In several studies, the neuroinflammatory reaction persisted as long as 1 year postinjury. Sekine *et al.* reported microglial activation lasting as long as 2 years following abstinence in cases of methamphetamine abuse.[[204](#)] In the Sandhir *et al.* study, they noted that the astrocytes react as if the injury were more severe than it actually was. It is important to note that astrocytic activation inhibits CNS regeneration.[[200](#)] In addition, elevated GFAP and S100B levels have been used as indicators of a poor clinical outcome in human beings after TBI.[[98](#)]

These results also show that the microglia respond faster than the astrocytes. Because astrocytes are major repositories of glutamate and GSH, under pathological conditions, they become sources of toxic levels of extraneuronal glutamate. And, as the major source for neuronal GSH, suppression of GSH synthesis by high levels of glutamate by inhibition of the glutamate/cystine antiporter Xc<sup>-</sup> can significantly increase neuronal vulnerability to excitotoxicity, ROS/RNS and LPP toxicity, and injury by a number of common environmental neurotoxins. It has also been shown that the aging brain has a reduced activity of peroxisome proliferator-activated receptor (PPAR)- $\gamma$  and  $\beta$  and increase activation of nuclear factor kappa B, which is linked to inflammation and prostaglandin activation. PPARs are a group of nuclear receptor proteins that play essential role in cell differentiation, metabolism, and in reducing inflammation. Of importance to this discussion is their role in reducing inflammation.

# LINK TO BETA-AMYLOID AND HYPERPHOSPHORYLATED TAU

## Traumatic brain injury and amyloid processing

Senile plaques and NFT are considered hallmarks of AD, especially NFTs, even though there is some dispute as to their essential role in the neurodegenerative process. Although McKee and co-workers found no beta-amyloid accumulation in their cases of CTE, others have reported abundant amyloid deposits.[[156](#)] Amyloid deposits are known to occur rapidly after TBI and persist in 30% of severe head trauma cases, even in children.[[193,193](#)]

A study by Uryu *et al.* sheds some light on a possible pathological link between TBI and amyloid accumulation in those with risk factors, such as APOE4.[[240](#)] Using a recently developed mTBI model in which the skull is exposed but not the dura, they examined the effect of single and repetitive mTBI on cognition, motor behavior, and the onset and progression of amyloid deposits in Tg2576 and wild-type (WT) mice at 2 days and 8 and 16 weeks post-injury. Tg2576 mice spontaneously develop amyloid plaque. The sham-operated mice underwent the exact same surgical procedure as the mTBI animals, but without the impact injury.

At baseline, both the Tg2676 mice and WT mice demonstrated similar abilities to learn visuo-spatial (V-S) tasks. WT animals subject to single or repetitive injury showed no difference in learning ability when examined at 16 weeks. The Tg2576 animals with a single injury also demonstrated no significant difference than sham-operated Tg2576 animals in V-S tasks. In contrast, the Tg2576 animals subjected to repetitive impact demonstrated a significant impairment of learning V-S task. That is, the repetitive traumatized Tg2576 animals demonstrated a significant cognitive impairment at 16 weeks postinjury.

Histological examinations of the WT mice demonstrated no cell loss after single mTBI in the ipsilateral cortex, hippocampal CA3, or dentate up to 16 weeks after injury. Repetitive injury produced a significantly higher accumulation of both soluble and insoluble A $\beta$  40 and 42 than did single injury. Although both injuries in this study caused an acceleration of amyloid production in the Tg2576 mice, there was a marked difference, favoring the repetitive injury model, in the extent of histological damage and levels of LPO. The greatest increase in amyloid deposits occurred at 16 weeks postinjury, with levels 4- to 10-fold higher than sham-operated Tg2576 mice. Higher levels were seen with repetitive injury as compared with single injury. These deposits were of greatest density in the olfactory bulb, frontal, cingulate, and hippocampus and spared the cerebellum, which is also spared in AD. The cortex had the highest density of A $\beta$  40 and 42, with smaller densities in the hippocampus.

It is of interest that LPO levels rose rapidly and were elevated at 12 weeks in the single impact animals, but returned to baseline levels by 16 weeks. In contrast, the repetitive injured animals demonstrated high levels of LPO as early as 9 weeks, which was maintained past 16 weeks. Importantly, cognitive impairment was seen only in the repetitively injured Tg2576 mice and persisted at 16 weeks. Previous studies have also shown that repetitive injuries are more likely to lead to CNS dysfunction and degeneration.[[74,127,213](#)]



LPO levels begin to increase a few months before amyloid plaques appear in the traumatized brain.[240] Similarly, microglial activation preceded neurodegeneration in experimental models and human disease.[176] A number of studies confirm progressive neurodegeneration in animal models of impact brain injury.[24,195] Smith *et al.* demonstrated progressive loss of neuronal tissue ipsilateral to the injury site that progressed over a year.[214] This included neuronal loss of pyramidal layer neurons within the cortex, thalamus, and septum. In most of these studies, ongoing microgliosis has been described.

## Quinolinic acid

One of the often-ignored excitotoxins linked to the neurodegeneration of CTE is QUIN, a metabolic product of kynurenine metabolism. Kynurenine is a tryptophan metabolite that breaks down into kynurenic acid and picolinic acid, both of which are neuroprotective, as well as neurodestructive QUIN.[93] Activated microglia can secrete large amounts of QUIN, which acts on the NMDA receptor to initiate excitotoxicity.[101] Under conditions of brain inflammation, indolamine-2,3-deoxygenase (IDO) is upregulated and this shifts kynurenine metabolism toward QUIN generation, which is especially driven by INF-gamma.[183] Elevations in QUIN can increase the generation of hyperphosphorylated tau, as do other excitotoxins.[131,188] Excitotoxins can also increase APP processing, resulting in an increase deposition of A beta in traumatized brain.[105] It has also been shown that INF- strongly induces IDO in primed microglia surrounding amyloid plaque, thus increasing the generation of QUIN.[254] QUIN has been shown to induce IL-1 $\beta$ , a key cytokine in AD pathogenesis.[90,233]

Because chronic inflammation appears to be involved in CTE, one must consider the effect of excitotoxicity caused by QUIN accumulation. The kynurenine pathway is activated in the AD brain and other neurodegenerative diseases, leading to an accumulation of QUIN.[91,94] QUIN can be produced by microglia, astrocytes, and macrophages and immunostaining studies have shown high levels of QUIN reactivity in the perimeter of senile plaques and NFTs.[91] Both low and high levels of QUIN can cause structural changes in neurons.[117] For example, chronic exposure of human neurons to QUIN even in concentrations of 100 nM can lead to dendrite beading, microtubule disruption, and a reduction in organelles.[117,253] In the AD brain, QUIN has been shown to accumulate in neurons, with high uptake in the entorhinal area and hippocampus.[91,92] It also co-localized with tau in cortical sections from AD patients. QUIN is found in significantly lower levels in the normal aging brain.

*In vitro* treatment of human fetal neurons with submicromolar concentrations of QUIN significantly increase Tau phosphorylation at multiple phosphorylation sites [Figure 10]. Rahman *et al.* demonstrated that QUIN causes a decrease in expression of serine/threonine protein phosphatases and this leads to tau hyperphosphorylation.[188] They also found that QUIN in concentrations of 500 nM and 1 200 nM significantly increased, not only total tau, but also tau phosphorylation at Tau-8 and Tau-180 epitopes. QUIN increased phosphorylation of serine 199/202 and threonine 231 in a dose-dependent manner. They also found that all concentrations of QUIN tested decreased phosphatase activity by approximately 30% and was not dose-dependent. QUIN also inhibits glutamate uptake and significantly inhibits glutamine synthetase activity in a dose-dependent manner, both of which enhance excitotoxicity.[227,233]

Glutamate and NMDA at equimolar concentrations (500 nM) also increased tau phosphorylation in a manner similar to QUIN. Various NMDA receptor blockers have been shown to selectively inhibit Tau phosphorylation (memantine, MK-801, and AP-5).[\[130,160\]](#) This suggest that QUIN-induced tau phosphorylation involves NMDA receptor activity.

Hyperphosphorylation of tau has been shown to disrupt and disassemble microtubules and lead to neurodegeneration and memory loss. It is known that several neuroinflammatory mediators can activate the kynurenine pathway, leading to production of QUIN by activated microglia and invading macrophages. Microglial activation is also known to occur early in models of tauopathies and immune suppression attenuates tau pathology.[\[259\]](#) The LPP 4-hydroxynonanal has been shown to prevent dephosphorylation of tau and promote tau crosslinking.[\[154\]](#) High levels of 4-HNE (4-hydroxynononeal) are generated by immunoexcitotoxicity.

Taken together, there is convincing evidence that TBI, especially repetitive injury, initiates the activation of innate brain immunity, which leads to transient immunoexcitotoxicity. Under normal conditions, this rapidly reverses as microglia assume a reparative phenotype. Preexisting brain pathology, even occult, or previous priming of microglia places the injured brain in a state of extended hyper-reactivity, which can lead to a prolonged cascade of immunoexcitotoxic events, eventually culminating in progressive neurodegeneration. As the brain ages, it becomes more vulnerable for a number of reasons, including progressive microglial activation and priming, attenuation of mitochondrial function, higher levels of inflammation, neuronal and glial dystrophy, reduced brain magnesium, periodic infections, and exposure to a number of environmental toxins and events. Compelling evidence suggests that immunoexcitotoxicity can lead to hyperphosphorylation of tau, increase the generation of neurotoxic levels of A $\beta$  oligomers, suppress mitochondrial migration to the synapse as well as depress mitochondrial function, increase the generation of ROS/RNS and LPP, all of which lead to synaptic and dendritic loss, pathophysiological events commonly seen in CTE.

## **THE ROLE OF IMMUNOEXCITOTOXICITY IN NEUROPSYCHIATRIC AND BEHAVIORAL DISORDERS**

Compelling research has linked excess glutamate stimulation and/or elevations of proinflammatory cytokines to a number of neuropsychiatric and behavioral conditions, many of which are seen with CTE. These include panic attacks, aggressive behavior, suicide, obsessive-compulsive disorder, anxiety, and depression.[\[39,54,112,162,236,243\]](#)

In a real life situation, one must also consider other exposures that can affect neurodegeneration and immunoexcitotoxicity. One study demonstrated microglial activation in human beings associated with illicit drug use in particular methamphetamines.[\[204\]](#) Buchanan and co-workers demonstrated that exposure to methamphetamine dramatically enhanced the proinflammatory response to systemic immune stimulation by LPS.[\[31\]](#) A similar situation could exist in the brain-injured athlete, since the microglia would already be primed by the concussion. Systemic infection, surgeries (even minor surgeries), and neuroinflammatory chemicals can act as the

systemic immune stimulus.[31] Regional microglial activation has also been demonstrated with alcohol abuse in human beings.[196]

Chronic alcoholism has been linked to supersensitization of receptor-mediated events, including  $\text{Ca}^{2+}$ -dependent processes, such as excitotoxicity.[100] Alcohol abuse is common among retired athletes and this could dramatically increase the neurodegenerative effects of immunoexcitotoxicity.

A number of studies strongly suggest that glutamate receptors are also playing a major role in addictive behaviors.[41,155,186] A combination of alcohol-related glutamate release and glutamate enhancement of addictive behaviors would make abstinence much more difficult.

Depression, a common finding with CTE, is closely correlated with IL-1 $\beta$  and IL-6 levels in plasma and CSF. Elevation in the same proinflammatory cytokines is also associated with the severity of depression.[119] In addition, newer studies have shown a strong correlation between brain glutamate levels and major depression, thus making a case for immunoexcitotoxicity in addictive disorders as well as associated neurodegeneration.[182,187] These studies also explain the link between immunoexcitotoxicity and neuropsychiatric and behavioral disorders associated with CTE.

## CONCLUSIONS

The development of CTE as a consequence of repeated, minor impact head injury has only recently been described. Although the final pathological manifestation closely resembles that of sporadic Alzheimer's disease, there are some differences, especially the predominance of tau pathology over amyloid accumulation in affected regions of the brain. Anatomical differences in the distribution of pathology are explained by the diffuse nature of TBI vs a spontaneous development as with AD.

A central mechanism responsible for this pathological and clinical picture has not been forthcoming, but in this paper, we present a central mechanism that may explain most of the features of the disorder, especially the pathogenesis of hyperphosphorylated tau proteins.

The interaction between glutamate receptors and specific cytokine receptors has been shown to result in a hyperreactive response of the microglia that was primed by the initial traumatic head injury or other events. Priming can occur not only from the initial impact, but also from systemic infections, certain toxic environmental exposures, including mercury, pesticide/herbicides, and latent virus infections within the brain. The latter may include cytomegalovirus and herpes simplex viruses.

Once primed, subsequent injuries can result in a hyperactive response of the microglia, resulting in a several fold higher release of immune cytokines, chemokines, and other immune mediators, as well as a massive release of the excitotoxins—glutamate, aspartate, and quiniolinic acid. Crosstalk between proinflammatory cytokines and glutamate receptors accelerate and worsen neurodegeneration in the affected areas. The frontal lobes, hippocampus, and parietal lobes show the greatest sensitivity to trauma-induced immunoexcitotoxicity.

Both inflammatory cytokines and excitotoxins can dramatically increase the generation of reactive oxygen and reactive nitrogen intermediates and an array of LPPs, both of which interfere with glutamate clearance, thus magnifying immunoexcitotoxicity over a prolonged period.

Repeated trauma to the brain may prevent the normal microglial switching from a proinflammatory mode to a reparative mode, resulting in chronic microglial immunoexcitotoxic activity and subsequent neurodegeneration. And, as demonstrated, several studies have shown that high levels of glutamate and quinolinic acid can significantly increase the deposition of hyperphosphorylated tau protein resulting in the observed NFT accumulation.

An integral part of this process is the effects of brain aging on the immunoexcitotoxic process. It is known that as the brain ages, microglia become primed. Under nonpathological conditions, these microglia are primed in a non-neurodestructive mode. In the face of either systemic infections, environmental toxic exposure or pre-existing brain pathology, the primed microglia become neurodestructive and may remain so for very prolonged periods. This explains why not all athletes are affected and provides a simple mechanism to explain the ongoing pathology being observed in the smaller number subjected to repeated minor head injuries. Also of importance would be levels of antioxidant enzymes, efficiency of glutamate removal systems, GSH levels, and dietary habits. This could also explain the observed differences in vulnerability.

With better methods of activated microglial scanning, we may be better able to demonstrate the dynamics of this process and design ways to reduce microglial activation, neuroinflammation, and immunoexcitotoxicity reactions.

## **Acknowledgments**

The authors acknowledge the financial support from the Dennis and Rose Heindl Foundation, the Mylan Laboratories Foundation, and the Nelson Peltz Foundation funds which were used for research and preparation of this manuscript. Financial disclosure:

Doctor Blaylock is the developer of Sports Brain Guard and Brain Repair Formula by Newport Nutritionals.

Doctor Maroon is a co-founder and stock holder in ImPACT Applications, Inc., Chairman of the Medical Advisory Board of General Nutrition Corporation, and a consultant to Nordic Naturals, Inc.

## **Footnotes**

Available FREE in open access from:

<http://www.surgicalneurologyint.com/text.asp?2011/2/1/107/83391>

## REFERENCES

1. Adams JH, Doyle D, Ford I, Gennarelli TA, Graham DI, McClellan DR. Diffuse axonal injury in head injury: definition, diagnosis and grading. *Histopathology*. 1989;15:49–59. [PubMed: 2767623]
2. Adams JH, Graham DI, Gennarelli TA, Maxwell WL. Diffuse axonal injury in non-missile head injury. *J Neurol Neurosurg Psychiatr*. 1991;54:481–3. [PMCID: PMC488581]
3. Alnoni S, Cervia D, Ross B, Montanari C, Gonzales AS, Sanchez-Alvez M, et al. Mapping of the full length and the truncated interleukin-18 receptor alpha in the mouse brain. *J Neuroimmunol*. 2009;214:43–54. [PMCID: PMC2745497] [PubMed: 19640592]
4. Andersson PB, Perry VH, Gordon S. Intracerebral injection of proinflammatory cytokines or leukocyte chemotaxins induces minimal myelomonocytic cell recruitment to the parenchyma of the central nervous system. *Brain*. 1997;120:435–44. [PMCID: PMC2119273] [PubMed: 1613459]
5. Anisman H. Cascading effects of stressors and inflammatory immune system activation: implication for major depressive disorder. *Rev Psychiatry Neurosci*. 2009;34:4–20. [PMCID: PMC2612083]
6. Arand M, Melzner H, Kinzl L, Bruckner UB, Gebhard F. Early inflammatory mediator response following isolated traumatic brain injury and other major trauma in humans. *Langenbecks Arch Surg*. 2001;386:241–8. [PubMed: 11466564]
7. Bal-Price A, Brown GC. Inflammatory neurodegeneration mediated by nitric oxide from activated glia-inhibiting neuronal respiration, causing glutamate release and excitotoxicity. *J Neurosci*. 2001;21:6480–91. [PubMed: 11517237]
8. Baltan S, Besancon EF, Mbow B, Ye Z, Hamner MA, Ransom BR. White matter vulnerability to ischemic injury increases with age because of enhanced excitotoxicity. *J Neurosci*. 2008;28:1479–89. [PubMed: 18256269]
9. Banati RB, Gehrman J, Schubert P, Kreutzberg GW. Cytotoxicity of microglia. *Glia*. 1993;7:111–8. [PubMed: 8423058]
10. Barrientos RM, Watkins LR, Rudy JW, Maier SF. Characterization of the sickness response in young and aging rats following *E.coli* infection. *Brain Behav Immun*. 2009;23:450–4. [PMCID: PMC2783183] [PubMed: 19486645]
11. Bashore TR, Ridderinkhof KR. Older age, traumatic brain injury, and cognitive slowing: some convergent and divergent findings. *Psychol Bull*. 2002;128:151–98. [PubMed: 11843546]

12. Bayier H, Marion DW, Puccio AM, Winiewski SR, Janesko KL, Clark RS, et al. Marked gender effect on lipid peroxidation after severe traumatic brain injury in adult patients. *J Neurotrauma*. 2004;21:1–8. [PubMed: 14987460]
13. Bell JD, Ai J, Chen Y, Baker AJ. Mild *in vitro* trauma induces rapid GluR2 endocytosis, robustly augments calcium permeability and enhances susceptibility to secondary excitotoxic insult in cultured Purkinje cells. *Brain*. 2007;130:2528–42. [PubMed: 17664176]
14. Beneveniste EN, Nyguyen VT, Wesemann DR. Molecular regulation of CD40 gene expression in macrophages and microglia. *Brain Behavior Immunol*. 2004;18:7–12.
15. Bernadino L, Xapelli S, Silva AP, Jakobsen B, Poulsen FR, Oliveira CR, et al. Modulator effects of interleukin-1 $\beta$  and tumor necrosis factor- $\alpha$  on AMPA-induced excitotoxicity in mouse organotypic hippocampal slice cultures. *J Neurosci*. 2005;25:6734–44. [PubMed: 16033883]
16. Betzen C, White R, Zehendner CM, Pietrowski E, Bender B, Luhmann HJ, et al. Oxidative stress upregulates NMDA receptor on cerebrovascular endothelium. *Free Radic Biol Med*. 2009;47:1212–20. [PubMed: 19660541]
17. Bigler ED. Quantitative magnetic resonance imaging in traumatic brain injury. *J Head Trauma Rehabil*. 2001;16:117–43. [PubMed: 11275574]
18. Bilbo SD, Barrientos RM, Eads AS, Northcutt A, Watkins LR, Rudy JW, et al. Early-life infection leads to altered BDNF and IL-1 $\beta$  mRNA expression in rat hippocampus following learning in adulthood. *Brain Behav Immunol*. 2008;27:451–5.
19. Blanc EM, Keller JN, Fernandez S, Mattson MP. 4-hydroxynonenal, a lipid peroxidation product, impairs glutamate transport in cortical astrocytes. *Glia*. 1998;22:149–60. [PubMed: 9537835]
20. Blaylock RL. A possible central mechanism in autism spectrum disorders, Part 2: immunexcitotoxicity. *Alt Ther Health Med*. 2009;15:60–7.
21. Blaylock RL. A possible central mechanism in autism spectrum disorders. In: Strunecka A, editor. *Cellular and Molecular Biology of Autism Spectrum Disorders*. Oak Park, IL: Bentham Science Publishing; 2011. pp. 47–72.
22. Block ML, Zecca L, Hong JS. Microglia-mediated neurotoxicity: uncovering the molecular mechanisms. *Nat Rev Neurosci*. 2007;8:57–69. [PubMed: 17180163]
23. Bochet P, Rossier J. Molecular biology of excitatory amino acid receptors: Subtypes and subunits. *EXS*. 1993;63:224–33. [PubMed: 8422537]



24. Bramlett HM, Dietrich WD. Quantitative structural changes in white and gray matter 1 year following traumatic brain injury in rats. *Acta Neuropathol.* 2002;103:607–14. [PubMed: 12012093]
25. Bronson JR, Manziolillo PA, Miller RJ. Ca<sup>2+</sup> entry via AMPA/KA receptors and excitotoxicity in cultured cerebellar Purkinje cells. *J Neurosci.* 1994;14:187–97. [PubMed: 7904304]
26. Brown GC, Cooper CE. Nanomolar concentrations of nitric oxide reversibly inhibit synaptosomal respiration by competing with oxygen at cytochrome oxidase. *FEBS Lett.* 1994;356:295–8. [PubMed: 7805858]
27. Brown GC. Mechanism of inflammatory neurodegeneration: iNOS and NADPH oxidase. *Biochem Soc Trans.* 2007;35:1119–21. [PubMed: 17956292]
28. Brown GC, Neher JJ. Inflammatory neurodegeneration and mechanisms of microglial killing of neurons. *Mol Neurobiol.* 2010;41:242–7. [PubMed: 20195798]
29. Brown JI, Baker AJ, Konasiewicz SJ, Moulton RJ. Clinical significance of CSF glutamate concentrations following severe traumatic brain injury in humans. *J Neurotrauma.* 1998;15:253–63. [PubMed: 9555971]
30. Brydon L, Walker C, Wawrzyniak A, Whitehead D, Okamura H, Yajima J, et al. Synergistic effects of psychological and immune stressors on inflammatory cytokine and sickness responses in humans. *Brain Behav Immun.* 2009;23:217–24. [PMCID: PMC2637301] [PubMed: 18835437]
31. Buchanan JB, Sparkman NL, Johnson RW. A neurotoxic regimen of methamphetamine exacerbates the febrile and neuroinflammatory response to a subsequent peripheral immune stimulus. *J Neuroinflammation.* 2010;7:82. [PMCID: PMC2995792] [PubMed: 21092194]
32. Buchhave P, Zetterberg H, Blennow K, Minthon L, Janciausk S, Hansson O. Soluble TNF receptors are associated with A $\beta$  metabolism and conversion to dementia in subjects with mild cognitive impairment. *Neurobiol Aging.* 2010;31:1877–84. [PubMed: 19070941]
33. Buki A, Povlishock JT. All roads lead to disconnection?—traumatic axonal injury revisited. *Acta Neurochir (Wien)* 2006;148:181–93. [PubMed: 16362181]
34. Butler MP, O'Connor JJ, Moynagh PN. Dissection of tumor-necrosis factor-alpha inhibition of long-term potentiation (LTP) reveals a p38 mitogen-activated protein kinase-dependent mechanism which maps to early-but not late-phase LTP. *Neuroscience.* 2004;124:319–26. [PubMed: 14980382]

35. Byram SC, Carson MJ, Deboy CA, Serpe CJ, Sanders VM, Jones KJ. CD4+ T cell-mediated neuroprotection requires dual compartment antigen presentation. *J Neurosci.* 2004;24:4333–9. [PMCID: PMC2665301] [PubMed: 15128847]
36. Byrnes KR, Loane DJ, Faden AI. Metabotropic glutamate receptors as targets for multipotential treatments of neurological disorders. *Neurotherapeutics.* 2009;6:94–107. [PMCID: PMC2634659] [PubMed: 19110202]
37. Campbell A, Becaria A, Lahiri DK, Sharman K, Bondy SC. Chronic exposure to aluminum in drinking water increases inflammatory parameters selectively in the brain. *J Neurosci Res.* 2004;75:565–72. [PubMed: 14743440]
38. Cao XZ, Ma H, Wang JK, Liu F, Tian AY, Wang LL, et al. Postoperative cognitive deficits and neuroinflammation in the hippocampus triggered by surgical trauma are exacerbated in aged rats. *Prog Neuropsychopharmacology Biol Psychiatry.* 2010;34:1426–32.
39. Chakrabarty K, Bhattacharyya S, Christopher R, Khanna S. Glutamatergic dysfunction in OCD. *Neuropsychopharmacology.* 2005;30:1735–40. [PubMed: 15841109]
40. Chamoun R, Suki D, Goodman JC, Robertson C. Role of extracellular glutamate measured by cerebral microdialysis in severe traumatic brain injury. *J Neurosurg.* 2010;113:564–70. [PMCID: PMC3464461] [PubMed: 20113156]
41. Chandler LJ, Newson H, Sumners C, Crews FT. Chronic alcohol exposure potentiates NMDA excitotoxicity in cerebral cortical neurons. *J Neurochem.* 1993;60:1578–81. [PubMed: 8455043]
42. Chao CC, Hu S, Ehrlich L, Peterson PK. Interleukin-1 and tumor necrosis factor- $\alpha$  synergistically mediate neurotoxicity: Involvement of nitric oxide and of N-methyl-D-aspartate receptors. *Brain Behav Immun.* 1995;9:355–65. [PubMed: 8903852]
43. Charleston JS, Body RL, Bolender RP, Mottet NK, Vahter ME, Burbacher TM. Changes in the number of astrocytes and microglia in the thalamus of the monkey *Macaca fascicularis* following long-term subclinical methylmercury exposure. *Neurotoxicology.* 1996;17:127–38. [PubMed: 8784824]
44. Chen XH, Johnson VE, Uryu K, Trojanowski JQ, Smith DH. A lack of amyloid plaques despite persistent accumulation of amyloid beta in axons of long-term survivors of traumatic brain injury. *Brain Path.* 2009;19:214–23. [PMCID: PMC3014260] [PubMed: 18492093]
45. Chen XH, Siman R, Iwata A, Meaney DF, Trojanowski JQ, Smith DH. Long-term accumulation of amyloid-beta, beta-secretase, presenilin-1, and caspase-3 in damaged axons following brain trauma. *Am J Pathol.* 2004;165:357–71. [PMCID: PMC1618579] [PubMed: 15277212]

46. Cherian L, Hiatky R, Robertson CS. Nitric oxide in traumatic brain injury. *Brain Path.* 2004;14:195–201. [PubMed: 15193032]
47. Chiaretti A, Antonelli A, Riccardi R, Genovese O, Pezzotti P, Di Rocco C, et al. Nerve growth factor expression correlates with severity and outcome of traumatic brain injury in children. *Eur J Paediatr Neurol.* 2008;12:195–204. [PMCID: PMC3704228] [PubMed: 17881264]
48. Choi DW. Glutamate neurotoxicity in cortical cell culture is calcium dependent. *Neurosci Lett.* 1985;58:293–7. [PubMed: 2413399]
49. Chua TC, Wen W, Slavin MJ, Sachdev PS. Diffusion tensor imaging in mild cognitive impairment and Alzheimer's disease: A review. *Curr Opin Neurol.* 2008;21:83–92. [PubMed: 18180656]
50. Ciccarelli O, Werring DJ, Wheller-Kingshott CA, Barker GL, Parker GJ, Thompson AJ, et al. Investigation of MS-normal-appearing brain using diffusion tensor MRI with clinical correlations. *Neurology.* 2001;56:926–33. [PubMed: 11294931]
51. Combrinck MI, Perry VH, Cunningham C. Peripheral infection evokes exaggerated sickness behavior in pre-clinical murine prion disease. *Neuroscience.* 2002;112:7–11. [PubMed: 12044467]
52. Conti B, Tabarean L, Sanchez-Alavez M, Davis C, Brownell S, Behrens M, et al. Cytokine receptors in the brain. *Neuroimmune Biol.* 2008;6:21–38.
53. Corsellis JA, Bruton CJ, Freeman-Brown D. The aftermath of boxing. *Psychol Med.* 1973;3:270–303. [PubMed: 4729191]
54. Cortese BM, Phan KL. The role of glutamate in anxiety and related disorders. *CNS Spectr.* 2005;10:820–30. [PubMed: 16400245]
55. Cunningham C, Wilcockson DC, Campion S, Lunnon K, Perry VH. Central and systemic endotoxin challenges exacerbate the local inflammatory response and increase neuronal death during chronic neurodegeneration. *J Neurosci.* 2005;25:9275–84. [PubMed: 16207887]
56. Czigner A, Mihaly A, Farkas O, Buki A, Krisztin-Peva B, Dobo E, et al. Kinetics of the cellular immune response following closed head injury. *Acta Neurochir (Wien)* 2007;149:281–9. [PubMed: 17288002]
57. Dantzer R, Bluthé RM, Castanon N, Kelley KW, Konsman JP, Parnet P. Cytokines, Sickness Behavior, and Depression. In: Ader R, editor. *Psychoneuroimmunology.* Vol. 1. Amsterdam: Elsevier; 2007. pp. 281–318.

58. Dantzer R. Cytokine-induced sickness behavior: Mechanisms and implications. *Ann NY Acad Sci.* 2001;933:222–34. [PubMed: 12000023]
59. Dantzer R, O'Connor JC, Freund GG, Johnson RW, Kelley KW. From inflammation to sickness and depression; when the immune system subjugates the brain. *Nat Rev Neurosci.* 2008;9:46–57. [PMCID: PMC2919277] [PubMed: 18073775]
60. Datta SG, Pillai SV, Rao SL, Kovoor JM, Chandramouli BA. Post-concussion syndrome: Correlation of neuropsychological deficits, structural lesions on magnetic resonance imaging and symptoms. *Neurol India.* 2009;57:594–8. [PubMed: 19934558]
61. De Stefano N, Matthews PM, Fu L, Narayanan S, Stanley J, Francis GS, et al. Axonal damage correlates with disability in patients with relapsing-remitting multiple sclerosis. Results of a longitudinal magnetic resonance spectroscopy study. *Brain.* 1998;121:1469–77. [PubMed: 9712009]
62. De Stefano N, Narayanan S, Francis GS, Arnaoutelis R, Tartaglia MG, Antel JP, et al. Evidence of axonal damage in the early stages of multiple sclerosis and its relevance to disability. *Arch Neurol.* 2001;58:65–70. [PubMed: 11176938]
63. Dean JM, Wang X, Kaindl AM, Gressens P, Fleiss B, Hagberg H, et al. Microglial MyD88 signaling regulates acute neuronal toxicity of LPS-stimulated microglia *in vitro*. *Brain Behav Immun.* 2010;24:776–83. [PubMed: 19903519]
64. DeFord SM, Wilson MS, Rice AC, Clausen T, Rice LK, Barabnova A, et al. Repeated mild brain injuries result in cognitive impairment in B6C3F1 mice. *J Neurotrauma.* 2002;19:427–38. [PubMed: 11990349]
65. Dilger RN, Johnson RW. Aging microglial cell priming, and the discordant central inflammatory response to signals from the peripheral immune system. *J Leukoc Biol.* 2008;84:932–9. [PMCID: PMC2538600] [PubMed: 18495785]
66. Dobson CB, Itzhaki RF. Herpes simplex virus type 1 and Alzheimer's disease. *Neurobiol Aging.* 1999;20:457–65. [PubMed: 10604441]
67. Doyle S, Pyndiah S, De Gois S, Erickson JD. Excitation-transcription coupling via calcium/calmodulin-dependent protein kinase/ERK1/2 signaling mediates the coordinate induction of VGLUT2 and Narp triggered by a prolonged increase in glutamatergic synaptic activity. *J Biol Chem.* 2010;285:14366–76. [PMCID: PMC2863170] [PubMed: 20212045]
68. Engberink RD, Blezer EL, Hoff EL, van der Pol SM, van der Toorn A, Dijkhuizen RM, et al. MRI of monocytes infiltration in an animal model of neuroinflammation using SPIO-labeled monocytes of free USPIO. *J Cereb Blood Flow Metab.* 2008;28:841–51. [PubMed: 18000513]

69. Engel S, Wehner HD, Meyermann R. Expression of microglial markers in the human CNS after closed head injury. *Acta Neurochir Suppl.* 1996;66:89–95. [PubMed: 8780804]
70. Feuerstein GZ, Wang X, Barone FC. The role of cytokines in the neuropathology of stroke and neurotrauma. *Neuroimmunomodulation.* 1998;5:143–59. [PubMed: 9730680]
71. Forlenza OV, Diniz BS, Talib LL, Mendonca VA, Ojopi EB, Gattaz WF, et al. Increased serum IL-1beta level in Alzheimer's disease and mild cognitive impairment. *Dement Geriatr Cogn Disord.* 2009;28:507–12. [PubMed: 19996595]
72. Forman AD. Neurologic complications of cytokine therapy. *Oncology (Williston Park)* 1994;8:105–10. [PubMed: 8003395]
73. Frank MG, Baratta MV, Sprunger DB, Watkins LR, Maier SF. Microglia serve as a neuroimmune substrate for stress-induced potentiation of CNS pro-inflammatory cytokine responses. *Brain Behav Immun.* 2007;21:47–59. [PubMed: 16647243]
74. Friess SH, Ichord RN, Ralston J, Ryall K, Helfaer MA, Smith C, et al. Repeated traumatic brain injury affects composite cognitive function in piglets. *J Neurotrauma.* 2009;26:1111–21. [PMCID: PMC2848948] [PubMed: 19275468]
75. Fukuda K, Alhara N, Sugar SM, Sharp FR, Pitts LH, Honkaniemi J, et al. Purkinje cell vulnerability to mild traumatic brain injury. *J Neurotrauma.* 1996;13:255–66. [PubMed: 8797175]
76. Gaetz M. The neurophysiology of brain injury. *Clin Neurophysiol.* 2004;115:4–18. [PubMed: 14706464]
77. Gahm C, Holmin S, Wiklund PN, Brundin L, Mathiesen T. Neuroprotection by selective inhibition of inducible nitric oxide synthase after experimental brain contusion. *J Neurotrauma.* 2006;23:1343–54. [PubMed: 16958586]
78. Gao HM, Hong JS, Zhang W, Liu B. Synergistic dopaminergic neurotoxicity of the pesticide rotenone and inflammogen lipopolysacchride: Relevance to the etiology of Parkinson's disease. *J Neurosci.* 2003;23:1228–36. [PubMed: 12598611]
79. Ghirnikar RS, Lee YL, Eng LF. Inflammation in traumatic brain injury: Role of cytokines and chemokines. *Neurochem Res.* 1998;23:329–40. [PubMed: 9482245]
80. Gilmer LK, Ansari MA, Roberts KN, Scheff SW. Age-related mitochondrial changes after traumatic brain injury. *J Neurotrauma.* 2010;27:939–50. [PMCID: PMC2943941] [PubMed: 20175672]

81. Glass TF, Reeves B, Sharp FR. The impact of excitotoxic blockade on the evolution of injury following combined mechanical and hypoxic insults in primary rat neuronal culture. *Neurobiol Dis.* 2004;17:378–84. [PubMed: 15571974]
82. Glazewski S, Skangiel-Kramska J, Kossut M. Development of NMDA receptor-channel complex and L-type calcium channels in mouse hippocampus. *J Neurosci Res.* 1993;35:199–206. [PubMed: 8100589]
83. Goldstein FC, Levin HS, Goldman WP, Clark AN, Altonen TK. Cognitive and neurobehavioral functioning after mild versus moderate traumatic brain injury in older adults. *J Int Neuropsychol Soc.* 2001;7:373–83. [PubMed: 11311038]
84. Goodman JC, Robertson CS, Grossman RG, Narayan RK. Elevation of tumor necrosis factor in head injury. *J Neuroimmunol.* 1990;30:213–7. [PubMed: 2229409]
85. Gorgulu A, Kitis T, Unal F, Turkoglu U, Kucuk M, Cobanoglu S. Protective effect of the N-methyl-D-aspartate receptor antagonists, MK-801 and CPP on cold-induced brain oedema. *Acta Neurochir (Wien)* 1999;141:93–8. [PubMed: 10071692]
86. Gouix E, Leveille F, Nicole O, melon C, Had-Aissouni L, Buisson A. Reverse glial glutamate uptake triggers neuronal death through extrasynaptic NMDA receptor activation. *Mol Cell Neurosci.* 2009;40:463–73. [PubMed: 19340933]
87. Gravius A, Pietraszek M, Dekundy A, Danysz W. Metabotropic glutamate receptors as therapeutic targets for cognitive disorders. *Curr Top Med Chem.* 2010;10:187–206. [PubMed: 20170472]
88. Greene JG. Mitochondrial function and NMDA receptor activation: mechanisms of secondary excitotoxicity. *Funct Neurol.* 1999;14:171–84. [PubMed: 10568220]
89. Greenwald RM, Gwin JT, Chu JJ, Crisco JJ. Head impact severity measures for evaluating mild traumatic brain injury risk exposure. *Neurosurgery.* 2008;62:789–98. [PMCID: PMC2790598] [PubMed: 18496184]
90. Griffin WS, Liu L, Li Y, Mrak RE, Barger SW. Interleukin-1 mediates Alzheimer and Lewy body pathologies. *J Neuroinflammation.* 2006;3:5. [PMCID: PMC1435743] [PubMed: 16542445]
91. Guillemain GJ, Brew BJ. Implications of the kynurenine pathway and quinolinic acid in Alzheimer's disease. *Redox Rep.* 2002;7:199–206. [PubMed: 12396664]
92. Guillemain GJ, Brew BJ, Noonan CE, Takikawa O, Cullen KM. Indolamine 2,3 dioxygenase and quinolinic acid immunoreactivity in Alzheimer's disease hippocampus. *Neuropathol Appl Neurobiol.* 2005;31:395–404. [PubMed: 16008823]



93. Guillemin GJ, Cullen KM, Lim CK, Smythe GA, Gardner B, Kapoor V, et al. Characterization of the kynurenine pathway in human neurons. *J Neurosci.* 2007;27:12884–92. [PubMed: 18032661]
94. Guillemin GJ, Meininger V, Brew BJ. Implications for the kynurenine pathway and quinolinic acid in amyotrophic lateral sclerosis. *Neurodegener Dis.* 2005;2:166–76. [PubMed: 16909022]
95. Gupta S, Knight AG, Gupta S, Knapp PE, Hauser KF, Keller JN, et al. HIV-Tat elicits microglial glutamate release: role of NADPH oxidase and the cystine-glutamate antiporter. *Neurosci Lett.* 2010;485:233–6. [PMCID: PMC2956797] [PubMed: 20849923]
96. Guskiewicz KM, McCrea M, Marshall SW, Cantu RC, Randolph C, Barr W, et al. Cumulative effects associated with recurrent concussion in collegiate football players. *JAMA.* 2003;290:2549–55. [PubMed: 14625331]
97. Hamm RJ, Odell DM, Pike BR, Lyeth BG. Cognitive impairment following traumatic brain injury: The effects of pre- and post-injury administration of scopolamine and MK-801. *Brain Res Cogn Brain Res.* 1993;1:223–6. [PubMed: 8003921]
98. Hayakata T, Schiozaki T, Tasaki O, Ikegawa H, Inoue Y, Toshiyuki F, et al. Changes in CSF S100B and cytokine concentrations in early-phase severe traumatic brain injury. *Shock.* 2004;22:101–7.
99. Hein AM, O'Banion MK. Neuroinflammation and memory: The role of prostaglandins. *Mol Neurobiol.* 2009;40:15–32. [PMCID: PMC3124778] [PubMed: 19365736]
100. He J, Crews FT. Increased MCP-1 and microglia in various regions of the human alcoholic brain. *Exp Neurol.* 2008;210:349–58. [PMCID: PMC2346541] [PubMed: 18190912]
101. Heyes MP, Achim CL, Wiley CA, Major EO, Saito K, Markey SP. Human microglia convert L-tryptophan into the neurotoxin quinolinic acid. *Biochem J.* 1996;320:595–7. [PMCID: PMC1217971] [PubMed: 8973572]
102. Holmin S, Soderlund J, Biberfeld P, Mathiesen T. Intracerebral inflammation after human brain contusion. *Neurosurgery.* 1998;42:291–8. [PubMed: 9482179]
103. Homsy S, Piaggio T, Croci N, Noble F, Plotkine M, Marchand-Leroux C, et al. Blockade of acute microglial activation by minocycline promotes neuroprotection and reduces locomotor hyperactivity after closed head injury in mice: A twelve week follow-up study. *J Neurotrauma.* 2010;27:911–21. [PubMed: 20166806]

104. Hong J, Cho IH, Kwak KI, Suh EC, Seo J, Min HJ, et al. Microglial toll-like receptor 2 contributes to kainate acid-induced glial activation and hippocampal neuronal cell death. *J Biol Chem.* 2010;285:39447–57. [PMCID: PMC2998094] [PubMed: 20923777]
105. Hu NW, Klyubin I, Anway R, Rowan MJ. GluN2B subunit-containing NMDA receptor antagonists prevent Aβ-mediated synaptic plasticity disruption *in vivo*. *Proc Natl Acad Sci U S A.* 2009;106:20504–9. [PMCID: PMC2787128] [PubMed: 19918059]
106. Huttemann M, Lee I, Kreipke CW, Petrov T. Suppression of inducible form of nitric oxide synthase prior to traumatic brain injury improves cytochrome c oxidase activity and normalizes cellular energy levels. *Neuroscience.* 2008;151:148–54. [PubMed: 18037245]
107. Igarashi T, Potts MB, Noble-Haeusslein LJ. Injury severity determines Purkinje cell loss and microglial activation in the cerebellum after cortical contusion injury. *Exp Neurol.* 2007;203:258–68. [PubMed: 17045589]
108. Imer M, Omay B, Uzunkol A, Erdem T, Sabanci PA, Karasu A, et al. Effect of magnesium, MK-801 and combination of magnesium and MK-801 on blood-brain barrier permeability and brain edema after experimental traumatic diffuse brain injury. *Neurol Res.* 2009;31:977–81. [PubMed: 19215660]
109. Inglese M, Makani S, Johnson G, Cohen BA, Silver JA, Gonen O, et al. Diffuse axonal injury in mild traumatic brain injury: a diffusion tensor imaging study. *J Neurosurg.* 2005;103:298–303. [PubMed: 16175860]
110. Israelsson C, Wang Y, Kylberg A, Pick CG, Hoffer BJ, Ebendal T. Closed head injury in a mouse model results in molecular changes indicating inflammatory responses. *J Neurotrauma.* 2009;26:1307–14. [PMCID: PMC2989856] [PubMed: 19317611]
111. Iwata A, Chen XH, McIntosh TK, Browne KD, Smith DH. Long-term accumulation of amyloid-beta in axons following brain trauma without persistent upregulation of amyloid precursor protein genes. *J Neuropath Exp Neurol.* 2002;61:1056–68. [PubMed: 12484568]
112. Janelidze S, Mattei D, Westrin A, Traskman-Bendz L, Brundin L. Cytokine levels in the blood may distinguish suicide attempters from depressed patients. *Brain Behav Immun.* 2011;25:335–9. [PubMed: 20951793]
113. Jawaid A, Rademakers R, Kass JS, Kalkonde Y, Schulz PE. Traumatic brain injury may increase the risk for frontotemporal dementia through reduced progranulin. *Neurodegener Dis.* 2009;6:219–20. [PMCID: PMC2837889] [PubMed: 20145419]
114. Jeohn GH, Kong LY, Wilson B, Hudson P, Hong JS. Synergistic neurotoxic effects of combined treatments with cytokines in murine primary mixed neuron/glia cultures. *J Neuroimmunol.* 1998;85:1–10. [PubMed: 9626992]

115. Jordan BD. Chronic traumatic brain injury associated with boxing. *Semin Neurol.* 2000;20:179–85. [PubMed: 10946737]
116. Jotwani V, Harmon KG. Postconcussion syndrome in athletes. *Curr Sports Med Rep.* 2010;9:21–6. [PubMed: 20071917]
117. Kerr SJ, Arnati PJ, Brew BJ. Neurocytotoxicity of quinolinic acid in human brain cultures. *J Neurovirol.* 1995;1:375–80. [PubMed: 9222380]
118. Kim YS, Tauber MG. Neurotoxicity of glia activated by gram-positive bacterial products depends on nitric oxide production. *Infect Immun.* 1996;64:3148–53. [PMCID: PMC174200] [PubMed: 8757846]
119. Konsman JP, Veeneman J, Combe C, Poole S, Luheshi GN, Dantzer R. Central nervous action of interleukin-1 mediates activation of limbic structures and behavioral depression in response to peripheral administration of bacterial lipopolysacchride. *Eur J Neurosci.* 2008;28:2499–510. [PubMed: 19087175]
120. Koura SS, Doppenberg EM, Marmarou A, Choi S, Young HF, Bullock R. Relationship between excitatory amino acid release and outcome after severe human head injury. *Acta Neurochir Suppl.* 1998;71:244–6. [PubMed: 9779196]
121. Kraus MF, Susmaras T, Caughlin BP, Walker CJ, Sweeney JA, Little DM. White matter integrity and cognition in chronic traumatic brain injury: a diffusion tensor imaging study. *Brain.* 2007;130:2508–19. [PubMed: 17872928]
122. Kuhlmann CR, Zehendner CM, Gerigk M, Closhen D, Bender B, Friedl P, et al. MK-801 blocks hypoxic blood-brain barrier disruption and leucocyte adhesion. *Neurosci Lett.* 2009;449:168–72. [PubMed: 18996441]
123. Kumar R, Husain M, Gupta RK, Hasan KM, Haris M, Agarwal AK, et al. Serial changes in the white matter diffusion tensor imaging metrics in moderate traumatic brain injury and correlation with neuro-cognitive function. *J Neurotrauma.* 2009;26:481–95. [PubMed: 19196176]
124. Lacroix S, Feinstein D, Rivest S. The bacterial endotoxin lipopolysacchride has the ability to target the brain in upregulating its membrane CD14 receptor within specific cellular populations. *Brain Pathol.* 1998;8:625–40. [PubMed: 9804372]
125. Langston JW, Fomo LS, Tetrud J, Reeves AG, Kaplan JA, Karluk D. Evidence of active nerve cell degeneration in the substantia nigra of humans years after 1-methyl-4-phenyl-1, 2, 3, 6-tetrahydropyridine exposure. *Ann Neurol.* 1999;46:598–605. [PubMed: 10514096]
126. Lauderback CM, Hacket JM, Huang FF, Keller JN, Szweda LI, Markesbery WR, Butterfield DA. The glial glutamate transporter, GLT-1 is oxidatively modified by 4-

- hydroxy-2-noneal in the Alzheimer's disease brain: The role of Abeta1-42. *J Neurochem.* 2001;78:413–6. [PubMed: 11461977]
127. Laurer HL, Bareyre FM, Lee VM, Trojanowski JQ, Longhi L, Hoover R, et al. Mild head injury increasing the brain's vulnerability to a second concussive impact. *J Neurosurg.* 2001;95:859–70. [PubMed: 11702878]
128. Lemstra AW, Groen in't Woud JC, Hoozemans JJ, van Haastert ES, Rozemuller AJ, Eikelenboom P, et al. Microglia activation in sepsis: A case-control study. *J Neuroinflammation.* 2007;15:4–4. [PMCID: PMC1783646] [PubMed: 17224051]
129. Lerner DM, Stroudmire A, Rosenstein DL. Neuropsychiatric toxicity associated with cytokine therapies. *Psychosomatics.* 1999;40:428–35. [PubMed: 10479948]
130. Liang Z, Liu F, Iqbal K, Grundke-Iqbal I, Gong CX. Dysregulation of tau phosphorylation in mouse brain during excitotoxic damage. *J Alzheimers Dis.* 2009;17:531–9. [PMCID: PMC2829309] [PubMed: 19363259]
131. Liao SL, Chen CJ. Differential effects of cytokines and redox potential on glutamate uptake in rat cortical glial cultures. *Neurosci Lett.* 2001;299:113–6. [PubMed: 11166951]
132. Lio D, Licastro F, Scola L, Chiappelli M, Grimaldi LM, Criverllo A, et al. Interleukin-10 promoter polymorphism is sporadic Alzheimer's disease. *Genes Immun.* 2003;4:234–8. [PubMed: 12700599]
133. Liu B, Wang K, Gao HM, Mandavilli B, Wang JY, Hong JS. Molecular consequences of activated microglia in the brain: Overactivation induces apoptosis. *J Neurochem.* 2001;77:182–9. [PubMed: 11279274]
134. Loane DJ, Byrnes KR. Role of microglia in neurotrauma. *Neurotherapeutics.* 2010;7:366–77. [PMCID: PMC2948548] [PubMed: 20880501]
135. Lovell MA, Ehmann WD, Mattson MP, Markesbery WR. Elevated 4-hydroxynoneal in ventricular fluid in Alzheimer's disease. *Neurobiol Aging.* 1997;18:457–61. [PubMed: 9390770]
136. Lukiw WJ, Bazan NG. Neuroinflammatory signaling upregulation in Alzheimer's disease. *Neurochem Res.* 2000;25:1173–84. [PubMed: 11059791]
137. Lu KT, Wang YW, Yang JT, Yang YL, Chen HI. Effect of interleukin-1 in traumatic brain injury-induced damage to hippocampal neurons. *J Neurotrauma.* 2005;22:885–95. [PubMed: 16083355]

138. Luo XG, Zhang JJ, Zhang CD, Liu R, Zheng L, Wang XJ, et al. Altered regulation of cd200 receptor in monocytes-derived macrophages from individuals with Parkinson's disease. *Neurochem Res.* 2010;35:540–7. [PubMed: 19924532]
139. Lynch MA. The multifaceted profile of activated microglia. *Mol Neurobiol.* 2009;40:139–56. [PubMed: 19629762]
140. Lyons A, Downer EJ, Crotty S, Noland YM, Millis KH, Lynch MA. CD200 ligand receptor interaction modulates microglial activation *in vivo* and *in vitro*: A role for IL-4. *J Neurosci.* 2007;27:8309–13. [PubMed: 17670977]
141. Lyons A, Lynch AM, Downer EJ, Hanley R, O'Sullivan JB, Smith A, et al. Fractalkine-induced activation of the Phosphatidylinositol-3 kinase pathway attenuates microglial activation *in vivo* and *in vitro*. *J Neurochem.* 2009;110:1547–56. [PubMed: 19627440]
142. Lyons A, McQuillian K, Deighan BF, O'Reilly JA, Downer EJ, Murphey AC, et al. Decreased neuronal CD200 expression in IL-4-deficient mice results in increased neuroinflammation in response to lipopolysaccharides. *Brain Behav Immun.* 2009;23:1020–7. [PubMed: 19501645]
143. Macciocchi SN, Barth JT, Littlefield LM. Outcome after mild head injury. *Clin Sports Med.* 1998;17:27–36. [PubMed: 9475968]
144. Maness LM, Kasten AJ, Banks WA. Relative contributions of a CVO and the microvascular bed to delivery of blood-borne IL-1alpha to the brain. *Am J Physiol.* 1998;275:E207–12. [PubMed: 9688620]
145. Mangano EN, Hayley S. Inflammatory priming of the substantia nigra influences the impact of later paraquat exposure: Neuroimmune sensitization of neurodegeneration. *Neurobiol Aging.* 2009;3:1361–78. [PubMed: 18187236]
146. Mao H, Liu B. Synergistic microglial reactive oxygen species generation induced by pesticides lindane and dieldrin. *Neuroreport.* 2008;19:1317–20. [PubMed: 18695515]
147. Markowitz AJ, White MG, Kolson DL, Jordan-Sciutto KL. Cellular interplay between neurons and glia: Towards a comprehensive mechanism for excitotoxic neuronal loss in neurodegeneration. *Cellscience.* 2007;4:111–46. [PMCID: PMC2613343] [PubMed: 19122795]
148. Marques CP, Cheeran MC, Plamquist JM, Hu S, Urban SL, Lokensgard JR. prolonged microglial cell activation and lymphocyte infiltration following experimental herpes encephalitis. *J Immunol.* 2008;181:6417–26. [PMCID: PMC2614272] [PubMed: 18941232]
149. Martland HS. Punch drunk. *JAMA.* 1928;91:1103–7.

150. Masocha W. Systemic lipopolysacchride (LPS)-induced microglial activation results in differential temporal reduction of CD200 and CD200 receptor gene expression in the brain. *J Neuroimmunol.* 2009;214:78–82. [PubMed: 19656578]
151. Mastrangelo MA, Sudol KL, Narrow WC, Bowers WJ. Interferon-(gamma) differentially affects Alzheimer's disease pathologies and induces neurogenesis in triple transgenic-AD mice. *Am J Pathol.* 2009;175:2076–88. [PMCID: PMC2774071] [PubMed: 19808651]
152. Masu M, Nakajima Y, Moriyoshi K, Ischii T, Akazawa C, Nakanashi S. Molecular characterization of NMDA and metabotropic glutamate receptors. *Ann NY Acad Sci.* 1993;707:153–64. [PubMed: 9137550]
153. Matser JT, Kessels AG, Jordan BD, Lezak MD, Troost J. Chronic traumatic brain injury in professional soccer players. *Neurology.* 1998;51:791–6. [PubMed: 9748028]
154. Mattson MP, Fu W, Waeg G, Uchida K. 4-hydroxynonenal, a product of lipid peroxidation, inhibits dephosphorylation of the microtubule-associated protein tau. *Neuroreport.* 1997;8:2275–81. [PubMed: 9243625]
155. McFarland K, Lapish CC, Kalivas PW. Prefrontal glutamate release into the core of the nucleus accumbens mediates cocaine-induced reinstatement of drug-seeking behavior. *J Neurosci.* 2003;23:3531–7. [PubMed: 12716962]
156. McKee AC, Cantu RC, Nowinski CJ, Hedley-Whyte ET, Gavett BE, Budson AE, et al. Chronic traumatic encephalopathy in athletes: Progressive tautopathy after repetitive head injury. *J Neuropathol Exp Neurol.* 2009;68:709–35. [PMCID: PMC2945234] [PubMed: 19535999]
157. McKracken E, Graham DI, Nilsen M, Stewart J, Nicoll JA, Horsburgh K. 4-hydroxynoneal immunoreactivity is increased in human hippocampus after global ischemia. *Brain Pathol.* 2001;11:14–21.
158. Melchior B, Puntambeker SS, Carson MJ. Microglia and the control of autoreactive T cell responses. *Neurochem Int.* 2006;49:145–53. [PMCID: PMC2626134] [PubMed: 16759751]
159. Meythaler JM, Peduzzi JD, Eleftheriou E, Noverack TA. Current Concepts: Diffuse axonal injury-associated traumatic brain injury. *Arch Phys Med Rehabil.* 2001;82:1461–71. [PubMed: 11588754]
160. Moinuevo JL, Liado A, Rami L. Memantine: Targeting glutamate excitotoxicity in Alzheimer's disease and other dementias. *Am J Alzheimers Dis Other Demen.* 2005;20:77–85. [PubMed: 15844753]



161. Moller T, Weinstein JR, Hanisch UK. Activation of microglial cells by thrombin: past, present, and future. *Semin Thromb Hemost.* 2006;32(Supp1):69–76. [PubMed: 16673268]
162. Moreau M, Andre C, O'Connor JC, Dumich SA, Woods JA, Kelley KW, et al. Inoculation of *Bacillus Calmette-Guerin* to mice induces an acute episode of sickness behavior followed by chronic depressive-like behavior. *Brain Behav Immun.* 2008;22:1087–95. [PMCID: PMC2908297] [PubMed: 18479887]
163. Moreira JD, Knorr L, Ganzella M, Thomazi AP, de Souza CG, de Souza DG, et al. Omega-3 fatty acids deprivation affects ontogeny of glutamatergic synapses in rats: relevance for behavior alterations. *Neurochem Int.* 2010;56:753–9. [PubMed: 20172010]
164. Moreno JA, Streifel KM, Sullivan KA, Legare ME, Tjalkens RB. Developmental exposure to manganese increases adult susceptibility to inflammatory activation of glia and neuronal protein nitration. *Toxicol Sci.* 2009;112:405–15. [PMCID: PMC2777079] [PubMed: 19812365]
165. Morganti-Kossmann MC, Rancan M, Otto VI, Stahel PF, Kossmann T. Role of cerebral inflammation after traumatic brain injury: Revisited concept. *Shock.* 2001;16:165–77. [PubMed: 11531017]
166. Morimoto K, Murasugi T, Oda T. Acute neuroinflammation exacerbates excitotoxicity in rat hippocampus *in vivo*. *Exp Neurol.* 2002;177:95–104. [PubMed: 12429214]
167. Nguyen MD, Julien JP, Rivest S. Innate immunity: The missing link in neuroprotection and neurodegeneration? *Nature Rev Neurosci.* 2002;3:216–27. [PubMed: 11994753]
168. Nicholls DG, Budd SL, Castilho RF, Ward MW. Glutamate excitotoxicity and neuronal energy metabolism. *Ann NY Acad Sci.* 1999;893:1–12. [PubMed: 10672225]
169. Nicholls DG. Oxidative stress and energy crises in neuronal dysfunction. *Ann NY Acad Sci.* 2008;1147:53–60. [PubMed: 19076430]
170. Niswender CM, Conn PJ. Metabotropic glutamate receptors: physiology, pharmacology, and disease. *Ann Rev Pharmacol Toxicol.* 2010;50:295–322. [PMCID: PMC2904507] [PubMed: 20055706]
171. Obrenovich TP, Urenjak J. Altered glutamatergic transmission in neurological disorders: From high extracellular glutamate to excessive synaptic efficacy. *Prog Neurobiol.* 1997;51:39–87. [PubMed: 9044428]
172. Ojala J, Alafuzoff I, Herukka SK, van Groen T, Tanila H, Pirttila T. Expression of interleukin-18 is increased in the brains of Alzheimer's disease patients. *Neurobiol Aging.* 2009;30:198–209. [PubMed: 17658666]

173. Olney JW, Sharpe LG. Brain lesions in an infant rhesus monkey treated with monosodium glutamate. *Science*. 1969;166:386–8. [PubMed: 5812037]
174. Omalu BI, DeKosky ST, Hamilton RL, Minster RL, Kamboh MI, Shakir AM, et al. Chronic traumatic encephalopathy in a national football league player: Part II. *Neurosurgery*. 2006;59:1086–92. [PubMed: 17143242]
175. Omalu BI, DeKosky ST, Minster RL, Kamboh MI, Hamilton RL, Wecht CH. Chronic traumatic encephalopathy in a National Football League player. *Neurosurgery*. 2005;57:128–34. [PubMed: 15987548]
176. Oswald MJ, Palmer DN, Kay GW, Shemilt SJ, Rezaie P, Cooper JD. Glial activation spreads from specific cerebral foci and precedes neurodegeneration in presymptomatic ovine neuronal ceroid lipofuscinosis (CLN6) *Neurobiol Dis*. 2005;20:49–63. [PubMed: 16137566]
177. Ouardouz M, Coderre E, Bask A, Chen A, Zamponi GW, Hameed S, et al. Glutamate receptors on myelinated spinal cord axons: I GluR6 kainate receptors. *Ann Neurol*. 2009;65:151–9. [PMCID: PMC2902553] [PubMed: 19224535]
178. Ouardouz M, Coderre E, Zamponi GW, Hameed S, Yin X, Trapp BD, et al. Glutamate receptors on myelinated spinal cord axons: II AMPA and GluR5 receptors. *Ann Neurol*. 2009;65:160–6. [PMCID: PMC3014988] [PubMed: 19224531]
179. Pais TF, Figueiredo C, Peixoto R, Braz MH, Chatterjee S. Necrotic neurons enhance microglial neurotoxicity through induction of glutaminase by a myD88-dependent pathway. *J Neuroinflammation*. 2008;5:43. [PMCID: PMC2572162]
180. Palmer AM, Marion DW, Botscheller ML, Swedlow PE, Styren SD, DeKosky ST. Traumatic brain injury-induced excitotoxicity assessed in a controlled cortical impact model. *J Neurochem*. 1993;61:2015–24. [PubMed: 7504079]
181. Palucha A, Pilc A. The involvement of glutamate in the pathophysiology of depression. *Drug News Perspect*. 2005;18:262–8. [PubMed: 16034483]
182. Paul IA, Skoinick P. Glutamate and depression: clinical and preclinical studies. *Ann NY Acad Sci*. 2003;1003:250–72. [PubMed: 14684451]
183. Pemberton LA, Kerr SJ, Smythe G, Brew BJ. Quinolinic acid production by macrophages stimulated with IFN-gamma, TNF alpha, and IFN-alpha. *J Interferon Cytokine Res*. 1997;17:589–95. [PubMed: 9355959]
184. Perry VH, Newman TA, Cunningham C. The impact of systemic infection on the progression of neurodegenerative disease. *Nat Rev Neurosci*. 2003;4:103–12. [PubMed: 12563281]

185. Petcu EB, Sfredel V, Platt D, Herndon JG, Kessler C, Popa-Wagner A. Cellular and molecular events underlying the dysregulated response of the aged brain to stroke: A mini-review. *Gerontology*. 2008;54:6–17. [PubMed: 18160818]
186. Pierce RC, Bell K, Duffy P, Kalivas PW. Repeated cocaine augments excitatory amino acid transmission in the nucleus accumbens only in rats having behavioral sensitization. *J Neurosci*. 1996;16:1550–60. [PubMed: 8778304]
187. Pittenger C, Sanacora G, Krystal JH. The NMDA receptor as a therapeutic target in major depressive disorder. *CNS Neurol Disord Drug Targets*. 2007;6:101–15. [PubMed: 17430148]
188. Rahman A, Ting K, Cullen KM, Brew BJ, Guillemin GJ. The excitotoxin quinolinic acid induces tau phosphorylation in human neurons. *PLoS One*. 2009;4:e6344. [PMCID: PMC2709912] [PubMed: 19623258]
189. Rancan M, Otto VI, Hans VH, Gerlach I, Jork R, Trentz O, et al. Upregulation of ICAM-1 and MCP-1 but not of MIP-2 and sensorimotor deficit in response to traumatic axonal injury in rats. *J Neurosci Res*. 2001;63:438–46. [PubMed: 11223919]
190. Ransohoff RM, Perry VH. Microglial physiology: Unique stimuli, specialized responses. *Ann Rev Immunol*. 2009;27:119–45. [PubMed: 19302036]
191. Ren K, Dubner R. Neuron-glia crosstalk gets serious: role on pain hypersensitivity. *Curr Opin Anesthesiol*. 2008;21:570–9. [PMCID: PMC2735048]
192. Rhodes JK, Sharkey J, Andrews PJ. The temporal expression, cellular localization, and inhibition of the chemokines MIP-2 and MCP-1 after traumatic brain injury in the rat. *J Neurotrauma*. 2009;26:507–25. [PubMed: 19210118]
193. Roberts GW, Gentleman SM, Lynch A, Graham DI. Beta A4 amyloid protein deposition in brain after head trauma. *Lancet*. 1991;338:1422–3. [PubMed: 1683421]
194. Roberts GW, Gentleman SM, Lynch A, Murray L, Landon M, Graham DI. Beta-amyloid protein deposition in the brain after severe head injury: Implications for the pathogenesis of Alzheimer's disease. *J Neurol Neurosurg Psychiatry*. 1994;57:419–25. [PMCID: PMC1072869] [PubMed: 8163989]
195. Rodriguez-Paez AC, Brunschwig JP, Bramlett HM. Light and electron microscopic assessment of progressive atrophy following moderate traumatic brain injury in the rat. *Acta Neuropathol*. 2005;109:603–16. [PubMed: 15877231]
196. Rosczyk HA, Sparkman NL, Johnson RW. Neuroinflammation and cognitive function in aged mice following minor surgery. *Exp Gerontol*. 2008;43:840–6. [PMCID: PMC2756971] [PubMed: 18602982]

197. Rousset CI, Kassem J, Olivier P, Chalon S, Gressens P, Saliba E. Antenatal bacterial endotoxin sensitizes the immature rat brain to postnatal excitotoxic injury. *J Neuropathol Exp Neurol.* 2008;67:994–1000. [PubMed: 18800008]
198. Ruppel RA, Kochanek PM, Adelson PD, Rose ME, Wisniewski SR, Bell MJ, et al. Excitatory amino acid concentrations in ventricular cerebrospinal fluid after severe traumatic brain injury in infants and children: the role of child abuse. *J Pediatr.* 2001;138:18–25. [PubMed: 11148507]
199. Sahuquillo J, Poca MA, Amoros S. Current aspects of pathophysiology and cell dysfunction after severe head injury. *Curr Pharm Des.* 2001;7:1475–503. [PubMed: 11562294]
200. Sandhir R, Onyszchuk G, Berman NE. Exacerbated glial response in the aged mouse hippocampal following controlled cortical impact injury. *Exp Neurol.* 2008;13:372–80. [PMCID: PMC2662478] [PubMed: 18692046]
201. Schmidt MV, Trumbach D, Weber P, Wagner K, Scharf SH, Liebl C, et al. Individual stress vulnerability is predicted by short-term memory and AMPA receptor subunit ratio in the hippocampus. *J Neurosci.* 2010;30:16949–58. [PubMed: 21159965]
202. Schwab JM, Seid K, Schuesener HJ. Traumatic brain injury induces prolonged accumulation of cyclooxygenase-1 expressing microglia/brain macrophages in rats. *J Neurotrauma.* 2001;18:881–90. [PubMed: 11565600]
203. Schwarcz R, Whetsell WO Jr, Mangano RM. Quinolinic acid: An endogenous metabolite that produces axon-sparing lesions in rat brain. *Science.* 1983;219:316–8. [PubMed: 6849138]
204. Sekine Y, Ouchi Y, Sugihara G, Takei N, Yoshikawa E, Nakamura K, et al. Methamphetamine causes microglial activation in the brains of human abusers. *J Neurosci.* 2008;28:5756–61. [PMCID: PMC2491906] [PubMed: 18509037]
205. Shao C, Roberts KN, Markesbery WR, Scheff SW, Lovel MA. Oxidative stress in head trauma in aging. *Free Radic Biol Med.* 2006;41:77–85. [PubMed: 16781455]
206. Sharp CD, Hines I, Houghton J, Warren A, Jackson TH, 4th, Jawahar A, et al. Glutamate causes a loss in human cerebral endothelial barrier integrity through activation of NMDA receptor. *Am J Physiol Heart Circ Physiol.* 2003;285:H2592–8. [PubMed: 12893641]
207. Sheng JG, Mrak RE, Griffin WS. Neuritic plaque evolution in Alzheimer's disease is accompanied by transition from primed to enlarged to phagocytic forms. *Acta Neuropathol.* 1997;94:1–5. [PubMed: 9224523]

208. Sherwood ER, Prough DS. Interleukin-8, neuroinflammation, and secondary brain injury. *Crit Care Med.* 2000;28:1221–3. [PubMed: 10809311]
209. Shijie J, Takeuchi H, Yawata I, Harada Y, Sonobe Y, Doi Y, et al. Blockade of glutamate release from microglia attenuates experimental autoimmune encephalomyelitis in mice. *Tohoku J Exp Med.* 2009;217:87–92. [PubMed: 19212100]
210. Shohami E, Beit-Yannai E, Horwitz M, Kohen R. Oxidative stress in closed-head injury: Brain antioxidant capacity as an indicator of functional outcome. *J Cereb Blood Flow Metab.* 1997;17:1007–19. [PubMed: 9346425]
211. Singhal A, Baker AJ, Hare GM, Reinders FX, Schlichter LC, Moulton RJ. Association between cerebrospinal fluid interleukin-6 concentration and outcome after severe human traumatic brain injury. *J Neurotrauma.* 2002;19:929–37. [PubMed: 12225653]
212. Singh IN, Sullivan PG, Hall ED. Peroxynitrite oxidative damage to brain mitochondria: protective effects of peroxynitrite scavengers. *J Neurosci Res.* 2007;85:2216–23. [PubMed: 17510982]
213. Slemmer JE, Matser EJ, De Zeeuw CI, Weber JT. Repeated mild injury causes cumulative damage to hippocampal cells. *Brain.* 2002;125:2699–709. [PubMed: 12429597]
214. Smith DH, Chen XH, pierce JE, Wolf JA, Trojanoski JQ, Graham DI, et al. Progressive atrophy and neuron death for one year following brain trauma in the rat. *J Neurotrauma.* 1997;14:715–27. [PubMed: 9383090]
215. Sparkman NL, Buchanan JB, Heyen JR, Chen J, Beverly JL, Johnson RW. Interleukin-6 facilitates liposacchride-induced distruption in working memory and expression of other proinflammatory cytokines in hippocampal neuronal cell layers. *J Neurosci.* 2006;26:10709–16. [PubMed: 17050710]
216. Sparkman NL, Johnson RW. Neuroinflammation associated with aging sensitizes the brain to the effects of infection or stress. *Neuroimmunomodulation.* 2008;15:323–30. [PMCID: PMC2704383] [PubMed: 19047808]
217. Stanika RI, Winters CA, Pivovarova NB, Andrews SB. Differential NMDA receptor-dependent calcium loading and mitochondrial dysfunction in CA1 vs CA3 hippocampal neurons. *Neurobiol Dis.* 2010;37:403–11. [PMCID: PMC2818520] [PubMed: 19879359]
218. Stebbins GT, Murphy CM. Diffusion tensor imaging in Alzheimer's disease and mild cognitive impairment. *Behav Neurol.* 2009;21:39–49. [PMCID: PMC3010401] [PubMed: 19847044]

219. Stellwagen D, Beattie EC, Seo JY, Malenka RC. Differential regulation of AMPA receptors and GABA receptor trafficking by tumor necrosis factor- $\alpha$ . *J Neurosci*. 2005;25:3219–28. [PubMed: 15788779]
220. Stitt JT. Passage of immunomodulators across the blood-brain barrier. *Yale J Biol Med*. 1990;63:121–31. [PMCID: PMC2589307] [PubMed: 2119089]
221. Stoll G, Bendszus M. Imaging of inflammation in the peripheral and central nervous system by magnetic resonance imaging. *Neuroscience*. 2009;158:1151–60. [PubMed: 18651996]
222. Streit WJ. Microglial response to brain injury: A brief synopsis. *Toxicol Pathol*. 2000;28:28–30. [PubMed: 10668987]
223. Streit WJ, Sammons NW, Kuhns AJ, Sparks DL. Dystrophic microglia in the aging human brain. *Glia*. 2004;45:208–12. [PubMed: 14730714]
224. Stys PK. White matter injury mechanisms. *Curr Mol Med*. 2004;4:113–30. [PubMed: 15032708]
225. Sun DA, Deshpande LS, Sombati S, Baranova A, Wilson MS, Hamm RJ, et al. Traumatic brain injury causes a long-lasting calcium ( $\text{Ca}^{2+}$ )-plateau of elevated intracellular Ca levels and altered  $\text{Ca}^{2+}$  homeostatic mechanisms in hippocampal neurons surviving brain injury. *Eur J Neurosci*. 2008;27:1659–72. [PMCID: PMC2617755] [PubMed: 18371074]
226. Takeuchi G, Jin S, Wang J, Zhang G, Kawanokuchi J, Kuno R, et al. Tumor necrosis factor- $\alpha$  induces neurotoxicity via glutamate release from hemichannels of activated microglia in an autocrine manner. *J Biol Chem*. 2006;281:21362–8. [PubMed: 16720574]
227. Tavares RG, Tasca CI, Santos CE, Wajner M, Souza DO, Dutra-Fiho CS. Quinolinic acid inhibits glutamate uptake into synaptic vesicles from rat brain. *Neuroreport*. 2000;11:249–53. [PubMed: 10674464]
228. Tekkok SB, Goldberg MP. AMPA/kainate receptor activation mediates hypoxic oligodendrocytes death and axonal injury in cerebral white matter. *J Neurosci*. 2001;21:4237–48. [PubMed: 11404409]
229. Tekkok SB, Ye Z, Ransom BR. Excitotoxic mechanisms of ischemic injury in myelinated white matter. *J Cereb Blood Flow Metab*. 2007;27:1540–2. [PubMed: 17299453]
230. Terpolilli NA, Zweckberger K, Trabold R, Schilling L, Schinzel L, Tegmeier F, et al. The novel nitric oxide synthase inhibitor 4-amino-tetrahydro-L-biopterine prevents brain edema formation and intracranial hypertension following traumatic brain injury in mice. *J Neurotrauma*. 2009;26:1963–75. [PubMed: 19514849]

231. Thurman DJ, Alverson C, Dunn KA, Guerrero J, Sniezek JE. Traumatic brain injury in the United States: A public health perspective. *J Head Trauma Rehabil.* 1999;14:602–15. [PubMed: 10671706]
232. Tikka T, Fiebich BL, Goldsteins G, Keinanen R, Koistinaho J. Minocycline, a tetracycline derivative, is neuroprotective against excitotoxicity by inhibiting activation and proliferation of microglia. *J Neurosci.* 2001;21:2580–8. [PubMed: 11306611]
233. Ting KK, Brew BJ, Guilleman GJ. Effect of quinolinic acid on human astrocytes morphology and functions: implications in Alzheimer's disease. *J Neuroinflammation.* 2009;6:36. [PMCID: PMC2797503] [PubMed: 20003262]
234. Tokuda T, Ikeda S, Yanagisawa N, Ihara Y, Glenner GG. Re-examination of ex-boxers' brains using immunohistochemistry with antibodies to amyloid beta-protein and tau protein. *Acta Neuropathol.* 1991;82:280–4. [PubMed: 1759560]
235. Tokutomi T, Migyagi T, Ogawa T, Ono J, Kawamata T, Sakamoto T, et al. Aged-associated increases in poor outcomes after traumatic brain injury: A report from the Japan Neurotrauma Data Bank. *J Neurotrauma.* 2008;25:1407–14. [PubMed: 19086809]
236. Tonelli LH, Stiller J, Rujescu D, Giegling I, Schneider B, Maurer K, et al. Elevated cytokine expression in the orbitofrontal cortex of victims of suicide. *Acta Psychiatr Scand.* 2008;117:198–206. [PMCID: PMC2612100] [PubMed: 18081924]
237. Trapp BD, Bo L, Mork S, Chang A. Pathogenesis of tissue injury in MS lesions. *J Neuroimmunol.* 1999;98:49–56. [PubMed: 10426362]
238. Tremnovler V, Beit-Yannai E, Younis F, Gallily R, Horowitz M, Shohami E. Antioxidants attenuate acute toxicity of tumor necrosis factor-alpha by brain injury in rat. *J Interferon Cytokine Res.* 1999;19:791–5. [PubMed: 10454350]
239. Uryu K, Chen XH, Martenez D, Braone KD, Johnson VE, Graham DI, et al. Multiple proteins implicated in neurodegenerative diseases accumulate in axons after brain trauma in humans. *Exp Neurol.* 2007;208:185–92. [PMCID: PMC3979356] [PubMed: 17826768]
240. Uryu K, Laurer H, McIntosh T, Pratico D, Martinez D, Leight S, et al. Repetitive mild brain trauma accelerates A $\beta$  deposition, lipid peroxidation, and cognitive impairment in a transgenic mouse model of Alzheimer amyloidosis. *J Neurosci.* 2002;15:446–54. [PubMed: 11784789]
241. Utagawa A, Truettner JS, Dietrich WD, Bramlett HM. Systemic inflammation exacerbates behavioral and histopathological consequences of isolated traumatic brain injury in rats. *Exp Neurol.* 2008;211:283–91. [PMCID: PMC2435258] [PubMed: 18355811]



242. Van Landeghem FK, Stover JF, Bechmann I, Bruck W, Unterberg A, Buhner C, et al. Early expression of glutamate transporter proteins in ramified microglia after controlled cortical impact injury in the rat. *Glia*. 2001;35:167–79. [PubMed: 11494408]
243. Vekovischeva OY, Aitta-Aho T, Echenko O, Kankaanpaa A, Seppala T, Honkanen A et al. Reduced aggression in AMPA-type glutamate receptor GluR-A subunit-deficient mice. *Genes Brain Behav*. 2004;3:253–65. [PubMed: 15344919]
244. Vereker E, O'Donnell E, Lynch MA. The inhibitory effect of interleukin-1 $\beta$  on long-term potentiation is coupled with increased activity of stress-activated protein kinases. *J Neurosci*. 2000;20:6811–9. [PubMed: 10995825]
245. Verkhratsky A. Neurotransmitter Receptors in astrocytes. In: Parpura V, Haydon PG, editors. *Astrocytes in, (Patho) Physiology of the Nervous System*. NY: Springer; 2009. pp. 49–67.
246. Von Bernhardi R, Tichauer JE, Eugenin J. Aging-dependent changes of microglial cells and their relevance for neurodegenerative disorders. *J Neurochem*. 2020;112:1099–114. [PubMed: 20002526]
247. Wagner AK, Bayir H, Ren D, Puccio A, Zafonte RD, Kochanek PM. Relationships between cerebrospinal fluid markers of excitotoxicity, ischemia, and oxidative damage after severe TBI: the impact of gender, age, and hypothermia. *J Neurotrauma*. 2004;21:125–36. [PubMed: 15000754]
248. Walker DG, Dalsong-Hernandez JE, Campbell NA, Lue LF. Decreased expression of CD200 and CD200 receptor in Alzheimer's disease: A potential mechanism leading to chronic inflammation. *Exp Neurol*. 2009;215:5–19. [PMCID: PMC2765462] [PubMed: 18938162]
249. Wallace KI, Lopez J, Shaffery JP, Wells A, Paul IA, Bennett WA. Interleukin-10/ceftriaxone prevents E.Coli-induced delays in sensorimotor task learning and spatial memory in neonatal and adult Sprague-Dawley rats. *Brain Res Bull*. 2010;81:141–8. [PMCID: PMC2908377] [PubMed: 19883741]
250. Wang X, Wang BR, Zhang XJ, Xu Z, Ding YQ, Ju G. Evidences for vagus nerve in maintenance of immune balance and transmission of immune information from gut to brain in STM-infected rats. *World J Gastroenterol*. 220:540–5. [PMCID: PMC4656439]
251. Weiss JH, Sensi SL. Ca<sup>2+</sup>-Zn<sup>2+</sup> permeable AMPA or kainate receptors: possible key factors in selective neurodegeneration. *Trends Neurosci*. 2000;23:365–71. [PubMed: 10906800]
252. Werner C, Englehard K. Pathophysiology of traumatic brain injury. *Br J Anesth*. 2007;99:4–9.

253. Whetsell WO Jr, Schwarcz R. Prolonged exposure to submicromolar concentrations of quinolinic acid causes excitotoxic damage in organotypic cultures of rat corticostriatal system. *Neurosci Lett*. 1989;97:272–5.
254. Yamada A, Akinoto H, Kagawa S, Guillemin GJ, Takikawa O. Proinflammatory cytokine interferon-gamma increases induction of indoleamine-2,3-dioxygenase in monocytic cells primed with amyloid beta peptide 1-42: implications for the pathogenesis of Alzheimer's disease. *J Neurochem*. 2009;110:791–800. [PubMed: 19457071]
255. Yamamoto T, Rossi S, Stiefel M, Doppenberg E, Zauner A, Bullock R, et al. CSF and ECF glutamate concentrations in head injured patients. *Acta Neurochir Suppl*. 1999;75:17–9. [PubMed: 10635370]
256. Yawata I, Takeuchi H, Doi Y, Liang J, Mizuno T, Suzumura A. Macrophage-induced neurotoxicity is mediated by glutamate and attenuated by glutaminase inhibitors and gap junction inhibitors. *Life Sci*. 2008;82:1111–6. [PubMed: 18452953]
257. Ye SM, Johnson RW. An age-related decline in interleukin-10 may contribute to the increased expression of interleukin-6 in brain of aged mice. *Neuroimmunomodulation*. 2001;9:183–92. [PubMed: 11847480]
258. Yi JH, Hazell AS. Excitotoxic mechanisms and the role of astrocytic glutamate transporters in traumatic brain injury. *Neurochem Int*. 2006;48:394–403. [PubMed: 16473439]
259. Yoshiyama Y, Higuchi M, Zhang B, Huang SM, Iwata N, Saido TC, et al. Synapse loss and microglial activation precede tangles in a P301S tauopathy mouse model. *Neuron*. 2007;53:337–51. [PubMed: 17270732]
260. Yoshiyama Y, Uryu K, Higuchi M, Longhi L, Hoover R, Fujimoto S, et al. enhanced neurofibrillary tangle formation, cerebral atrophy, and cognitive deficits induced by repetitive mild brain injury in a transgenic tauopathy mouse model. *J Neurotrauma*. 2005;22:1134–41. [PubMed: 16238489]
261. Zarkovic K. 4-hydroxynoneal and neurodegeneration. *Mol Aspects Med*. 2003;24:293–303. [PubMed: 12893007]
262. Ziaja M, Pyka J, Machowska A, Maslanka A, Plonka PM. Nitric oxide spin-trapping and NADPH-diaphorase activity in mature rat brain after injury. *J Neurotrauma*. 2007;24:1845–54. [PubMed: 18159996]

# Figures and Tables

Figure 1

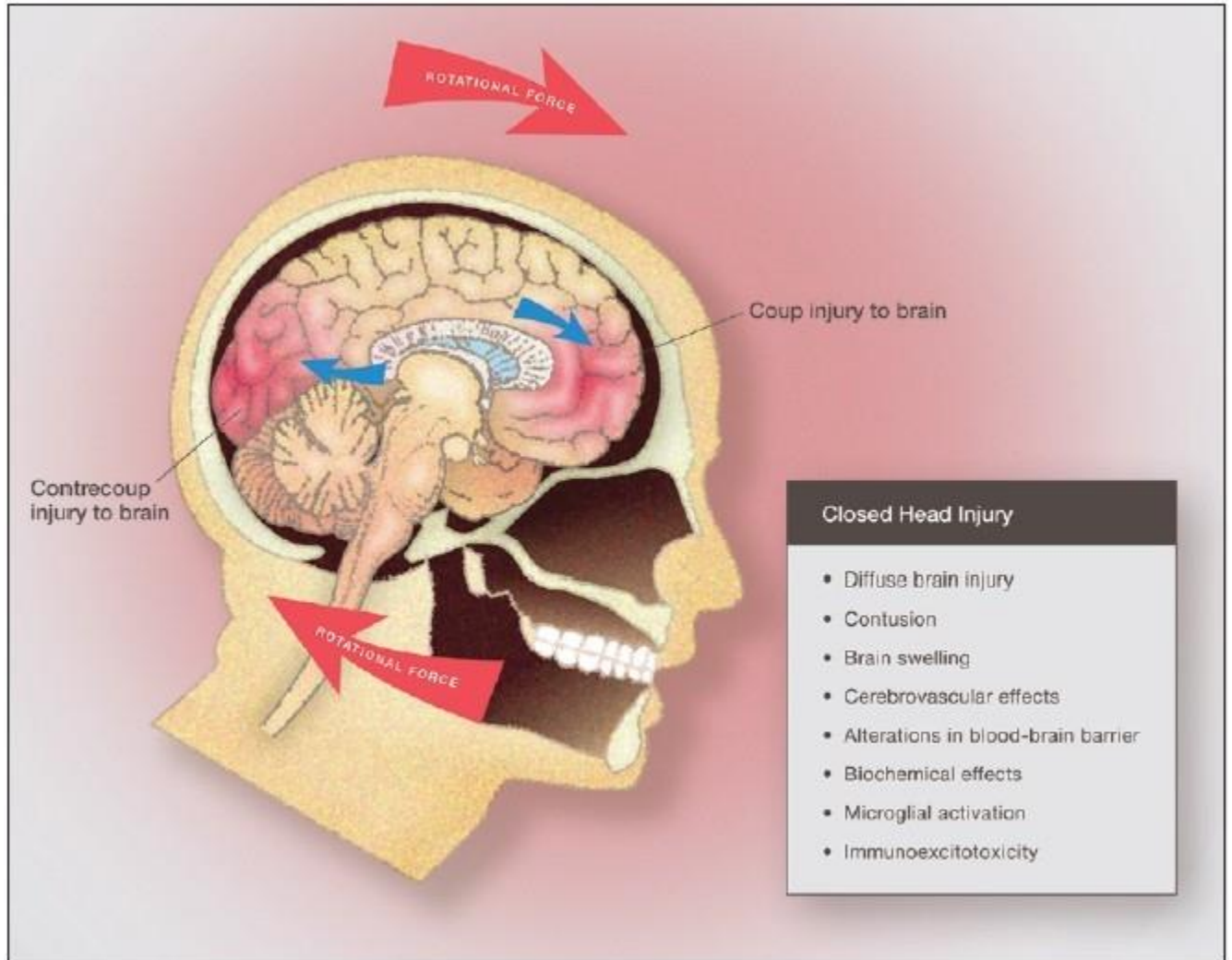


Illustration of closed brain injury demonstrating mechanical forces involved and the pathophysiological and biochemical effects of diffuse brain injury, which result in rapid microglial activation and immunoexcitotoxicity

**Figure 2**

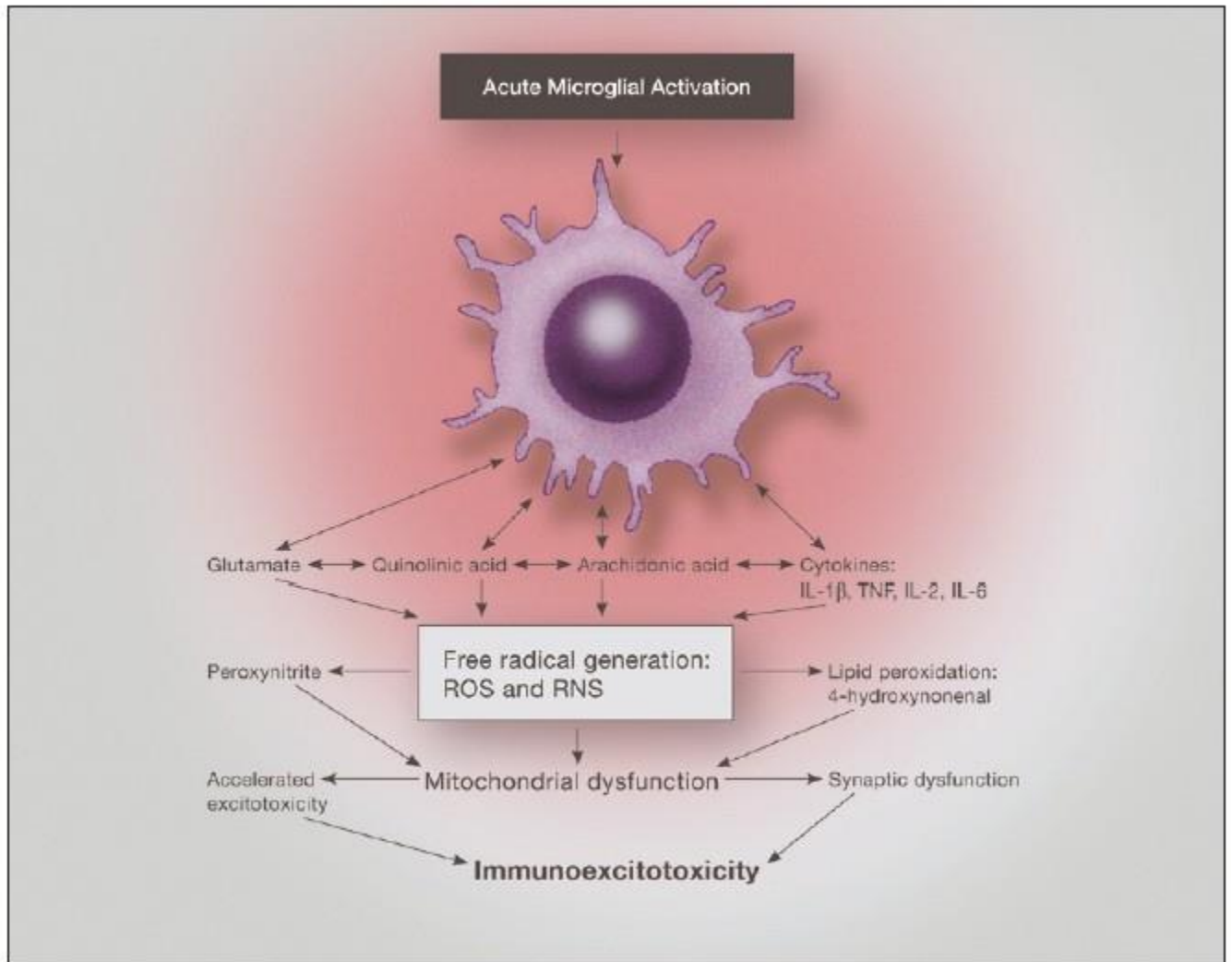


Illustration of the neurotoxic factors released from an activated microglia, demonstrating the interaction of proinflammatory cytokines and excitatory amino acids. Of particular importance is the effect on mitochondrial function, which when depressed enhances excitotoxic sensitivity as well as reactive oxygen species generation

**Figure 3**

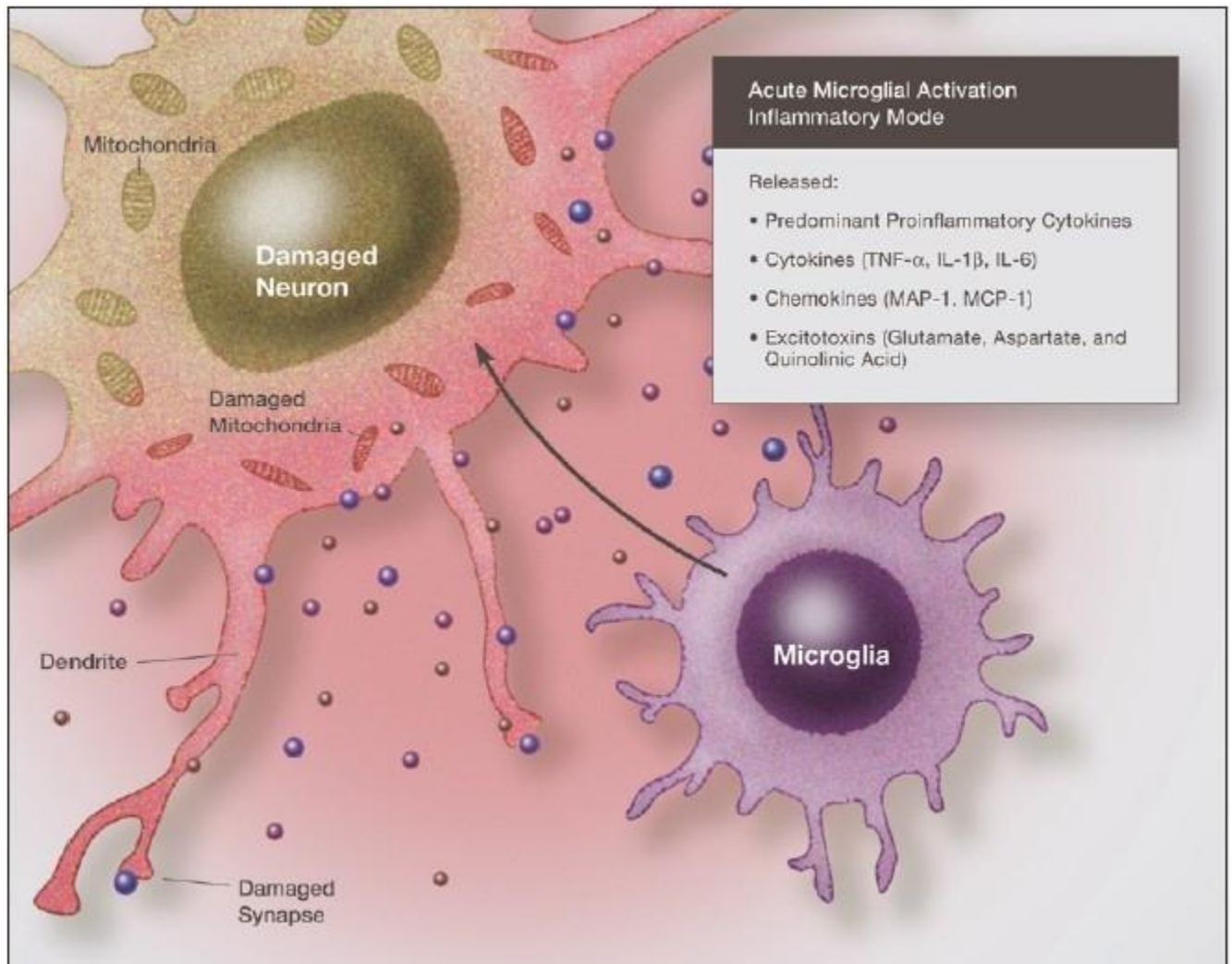


Illustration demonstrating the neurotoxic effects of proinflammatory cytokines and chemokines acting in synergy with excitatory amino acids. Immunoexcitotoxicity results in damage to neuronal cell membranes, mitochondria, DNA, as well as dendrites and synapses



**Figure 4**

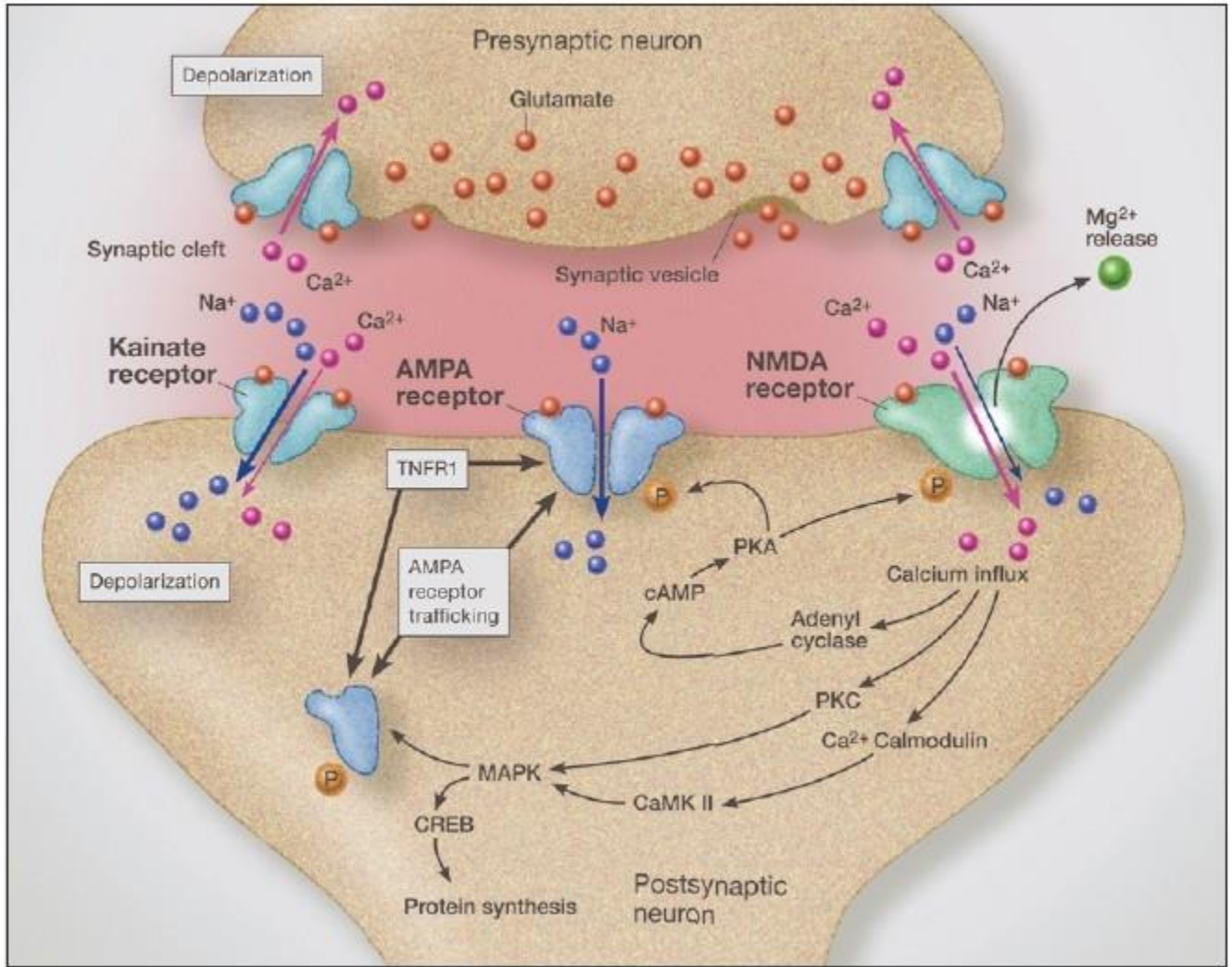


Illustration of glutamatergic synapse demonstrating AMPA receptor trafficking from the endoplasmic reticulum, which is driven by activation of tumor necrosis factor receptor-1. Crosstalk between the 2-amino-3-(5-methyl-3-oxo-1,2-oxazol-4-yl) propanoic acid receptor and tumor necrosis factor receptor-1 increase synaptic insertion of GluR2-lacking (calcium permeable) 2-amino-3-(5-methyl-3-oxo-1,2-oxazol-4-yl) propanoic acid receptors, thus increasing synaptic glutamate-related sensitivity. tumor necrosis factor receptor-1 activation also increases GABA receptor endocytosis, which increases synaptic sensitivity to excitotoxicity even further

Figure 5

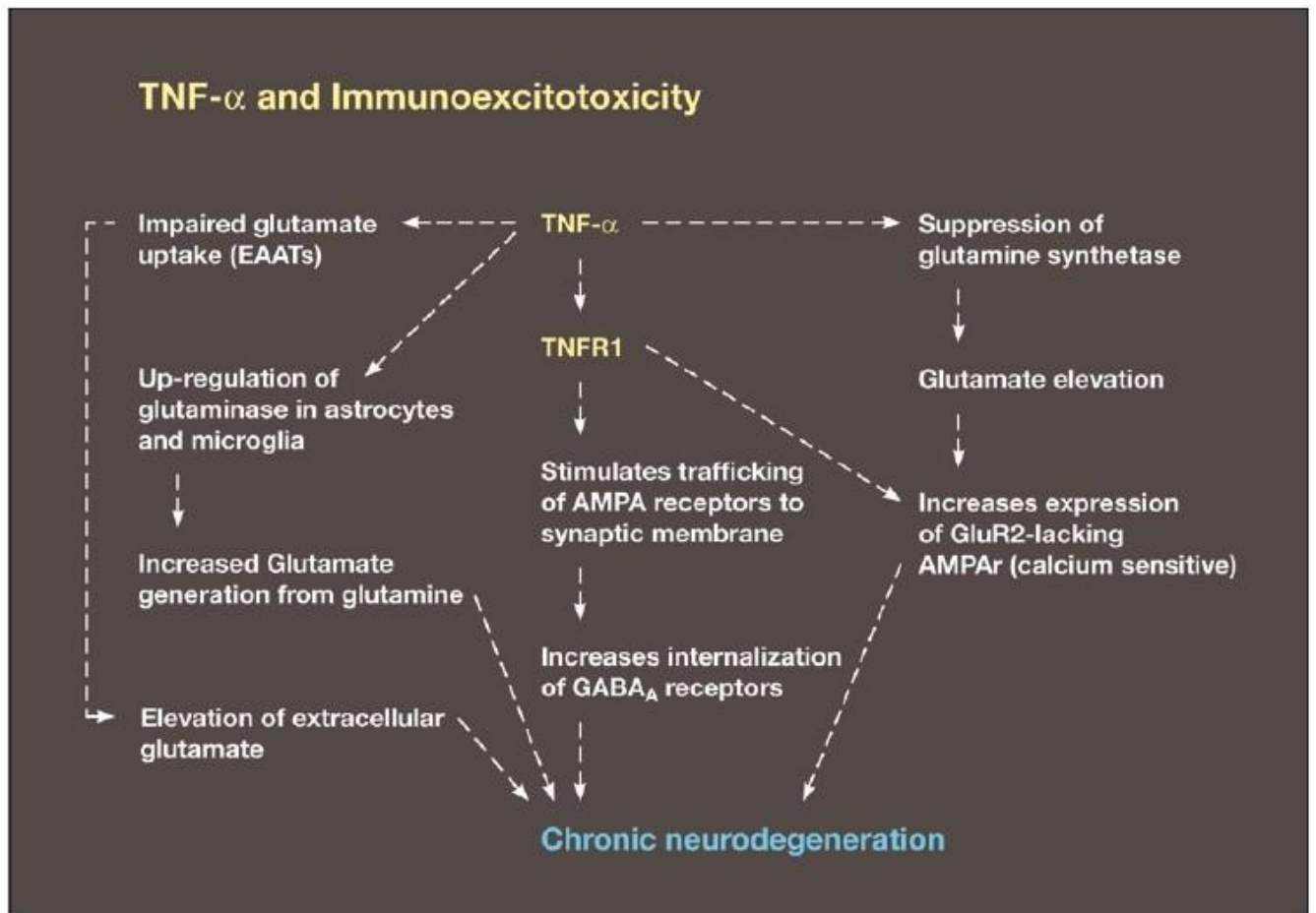


Diagram demonstrating a number of the major mechanisms of immunoexcitotoxicity, which includes the interaction of TNF- $\alpha$  with a number of systems that enhance excitotoxicity. This includes impaired glutamate transport, upregulation of glutaminase, suppression of glutamine synthetase, increased trafficking of AMPA receptors to synaptic lipid raft and endocytosis of GABA



**Figure 6**

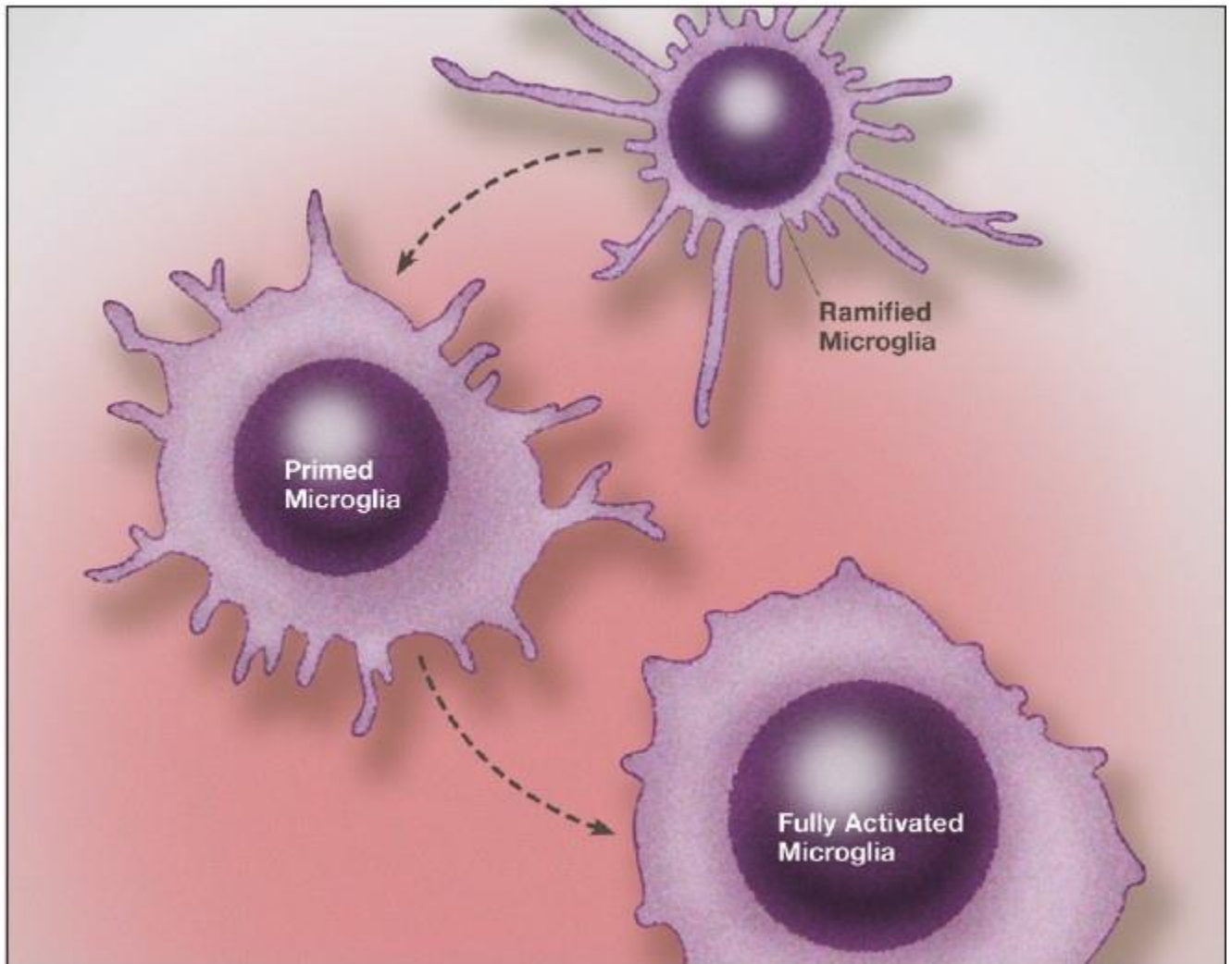


Illustration of microglia priming/activation transition states beginning from a resting (ramified) state. Recent studies indicate that microglia can assume a number of activation states, such as predominately phagocytic, predominately neuroprotective or predominately neurodestructive. In the primed state the mRNA for cytokines, chemokines and other reactive molecules are upregulated but active proteins are not released

**Figure 7**

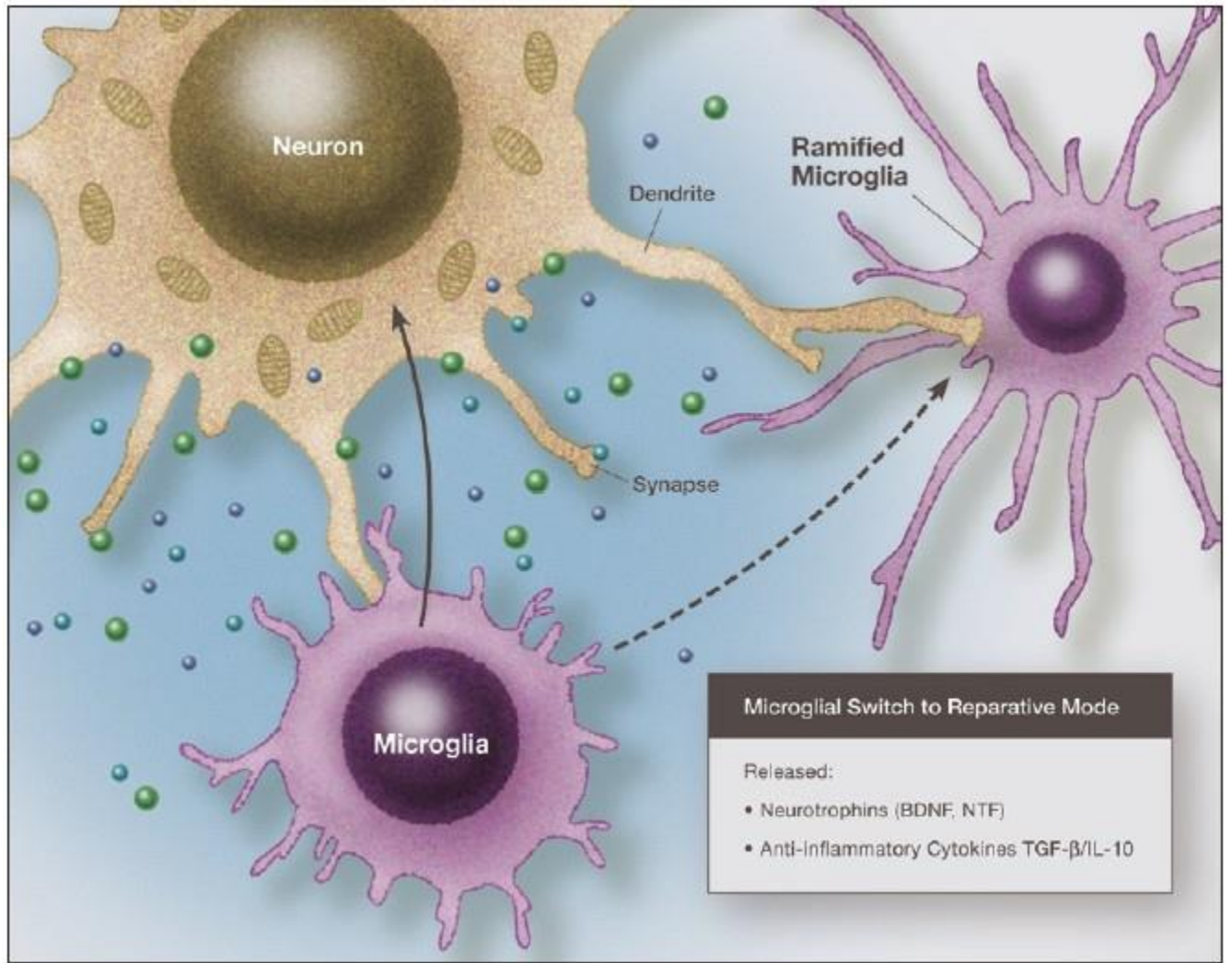


Illustration of a microglia in a predominately reparative mode, which will then switch to a resting (ramified) state. In the reparative mode it secretes neurotrophic factors and anti-inflammatory cytokines that shut off the inflammatory reaction

**Figure 8**

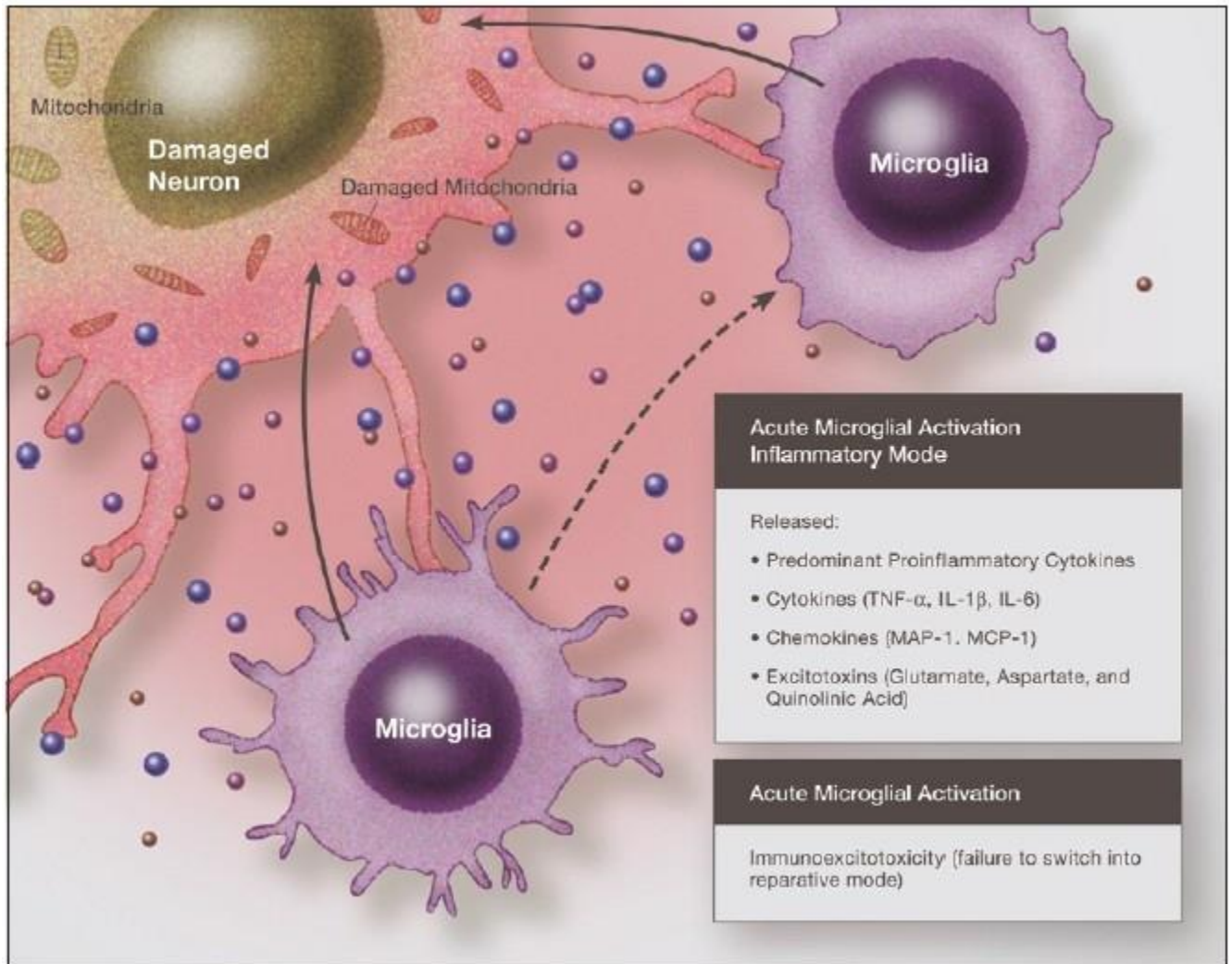


Illustration of an activated microglia that fails to switch from an activated, neurodestructive mode to a reparative mode or ramified state. Under such conditions immunoexcitotoxic reactions can continue for prolonged periods

**Figure 9**

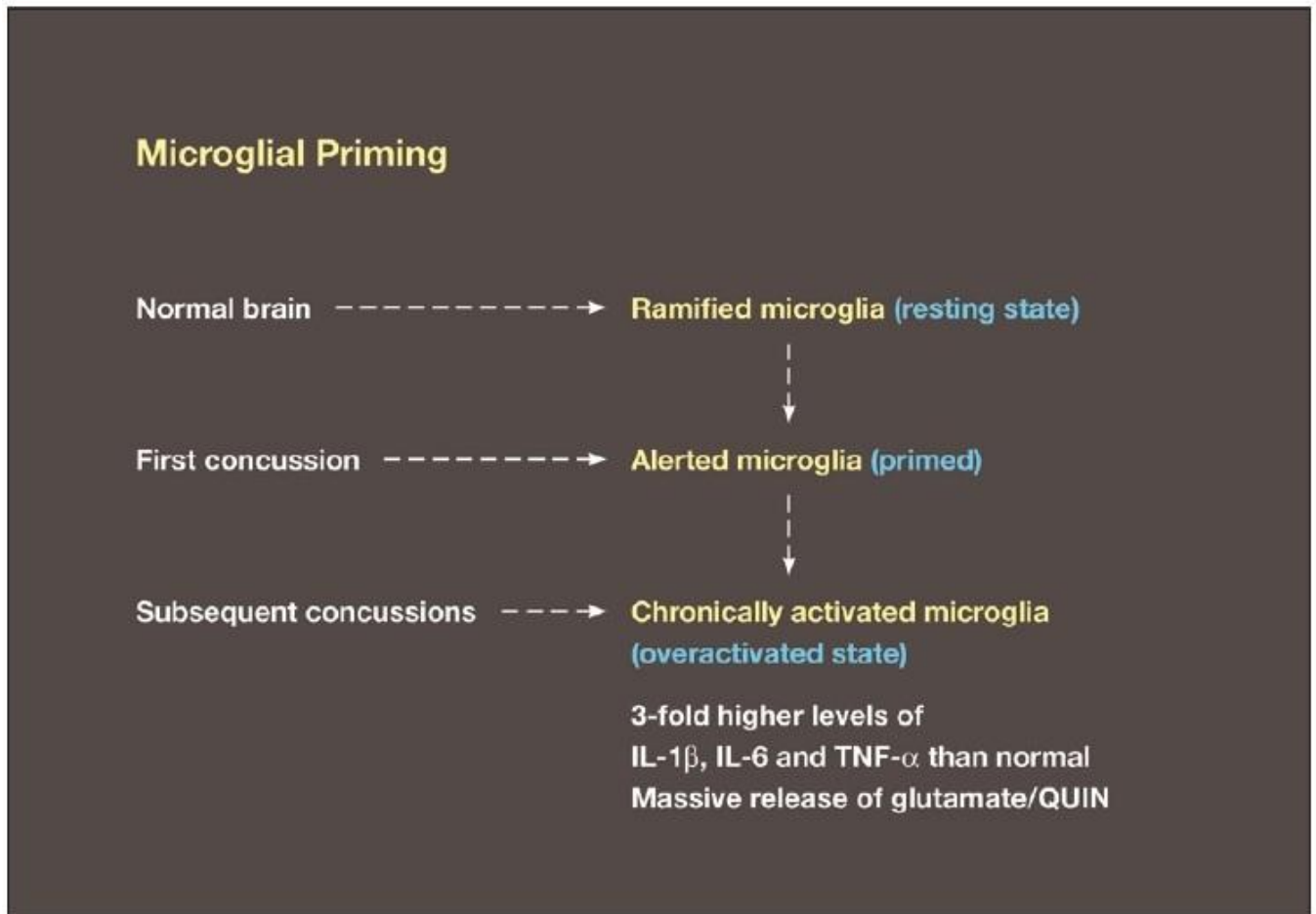
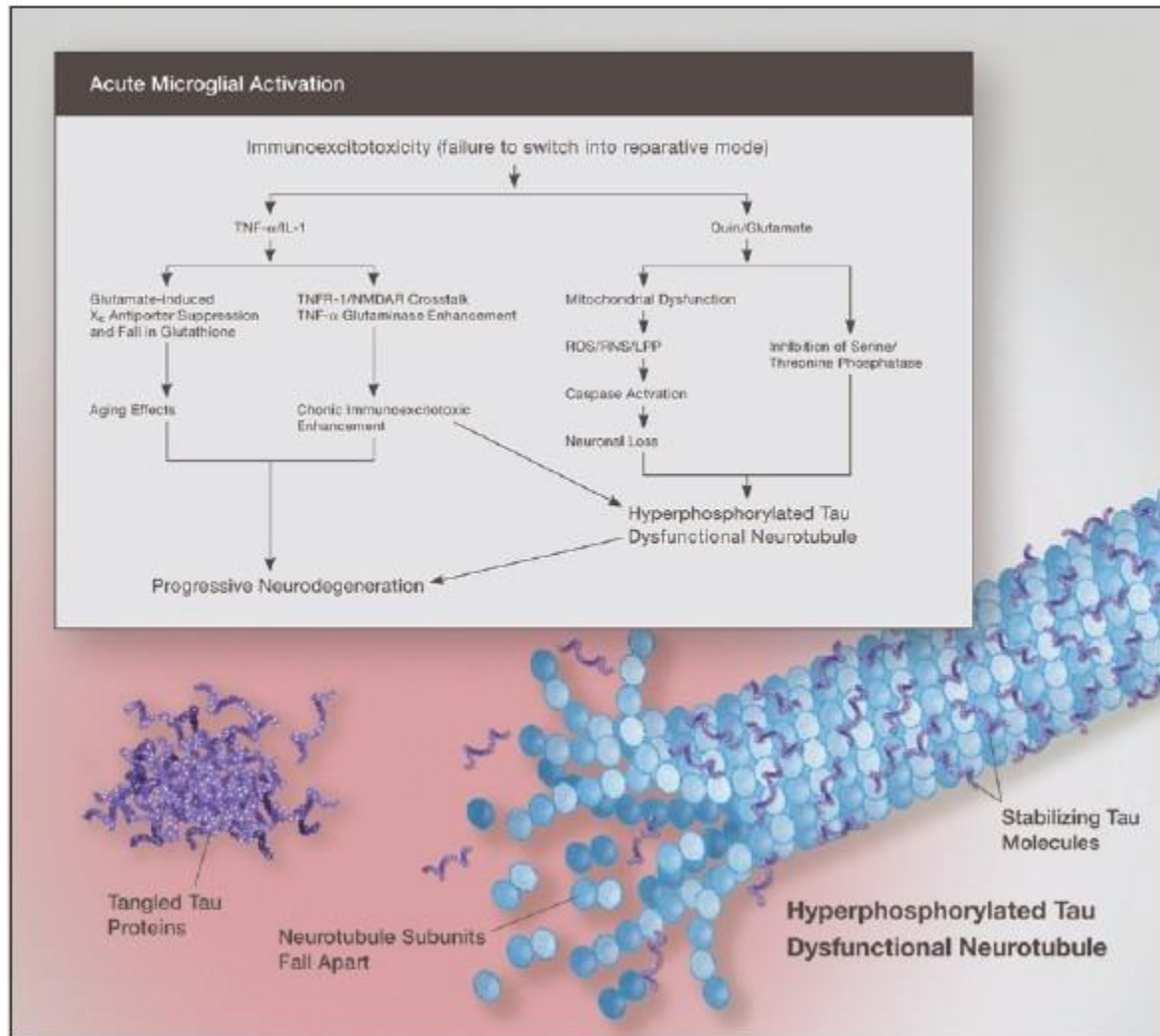


Diagram demonstrating the conversion of a resting microglia in the uninjured brain to a primed microglia with an initial injury. Subsequent injuries, even separated by prolonged periods, can then trigger a hyper-reaction by the fully activated microglia. This in turn results in a more intense immunoexcitotoxic reaction



**Figure 10**



Elevated glutamate and subsequent excitotoxicity is essential to neurodegeneration induced by elevated proinflammatory cytokines. With chronic brain inflammation, tryptophan metabolism by the kynurenine pathway shifts toward quinolinic acid generation, which is excitotoxic. Both elevated QUIN and glutamate levels inhibit phosphatases and this results in hyperphosphorylated tau and subsequent neurotubule dysfunction and neurofibrillary tangle deposition in the areas of the brain most affected by immunotoxicity