

Toxicol Int. 2015 Jan-Apr; 22(1): 152–157.

doi: [10.4103/0971-6580.172286](https://doi.org/10.4103/0971-6580.172286)

PMCID: PMC4721164

Food Color Induced Hepatotoxicity in Swiss Albino Rats, *Rattus norvegicus*

[Beenam Saxena](#) and [Shiv Sharma](#)

Department of Zoology, Bareilly College, Bareilly, Uttar Pradesh, India

Address for correspondence: Dr. Beenam Saxena, Department of Zoology, Bareilly College, Bareilly, Uttar Pradesh, India. E-mail: ni.oc.oohay@2791_maneeb

Copyright : © Toxicology International

This is an open access article distributed under the terms of the Creative Commons Attribution NonCommercial ShareAlike 3.0 License, which allows others to remix, tweak, and build upon the work non commercially, as long as the author is credited and the new creations are licensed under the identical terms.

Abstract

Objective:

Certain dietary constituents can induce toxicity and play a critical role in the development of several hepatic disorders. Tartrazine, metanil yellow and sunset yellow are widely used azo dyes in food products, so the present study is aimed to investigate the food color induced hepatotoxicity in Swiss albino rats.

Materials and Methods:

Swiss albino rats were divided into four groups, each group having six animals. Group I served as control, Group II, Group III and Group IV were administered with 25, 50 and 75 mg/kg body weight blend of sunset yellow, metanil yellow and tartrazine for 30 days. Hepatotoxicity in rats treated with a blend of these food colors was studied by assessing parameters such as serum total protein, serum albumin, serum alkaline phosphatase (ALP) as well as hepatic malondialdehyde (MDA). The activity of superoxide dismutase (SOD), reduced glutathione (GSH) and catalase (CAT) were assessed.

Results:

Significantly increased concentrations of serum total protein, serum albumin, serum ALP and hepatic MDA and significantly lowered levels of SOD, reduced GSH and CAT in the liver tissue of treated animals were observed when compared with control animals. The alteration in the liver includes necrosis of hepatocytes, infiltration and vacuolation.

Conclusion:

The result indicates that consumption of food color in diet induces liver tissue damage. The used doses of food color were mostly attributable to hepatocellular damage and drastic alteration in antioxidant defense system.

Keywords: Metanil yellow, sunset yellow, Swiss albino rat, tartrazine

INTRODUCTION

A number of food coloring additives are added to improve the appearance of the food items and drinks. Colorant provides an aesthetic appearance to food stuff. In India 83.6% of the sample contained permitted colors and 16.4% of sample contained non-permitted colors.[1] Tartrazine and sunset yellow found to be the two most frequently used colors. These are used to color bakery goods, cereals, beverages, candies, gelatin and numerous other commodities. The drinks and juices contributed to the maximum exposure of tartrazine and metanil yellow. Metanil yellow is used extensively for coating of turmeric and pulses. Exposures to various food colors can cause hepatotoxicity.[2] To classify a color as a harmful agent to human depends on its ability to cause hepatocyte damage due to metabolic activation of the compounds to highly free radical products. These free radical products induce lipid peroxidation which is believed to be one cause of cell membrane damage leading to a number of pathological events. The principle effect of food colors may cause hepatic damage by increasing lipid peroxidation; decreasing activities of antioxidant enzyme such as superoxide dismutase (SOD), catalase (CAT), non-enzymatic reduced glutathione (GSH) and elevation of hepatic enzyme, alkaline phosphatase (ALP).[3] ALP is a reliable marker of hepatobiliary dysfunction due to damage. Malondialdehyde (MDA) is one of the end products of lipid peroxidation and a measure of free radical generation.

Thus, the aim of this study is to determine the toxicity of food colors in albino rat by determining some of the biochemical parameters including activities of ALP, total protein and albumin in serum as well as oxidative stress parameters such as SOD, CAT, GSH and MDA in liver tissue.

MATERIALS AND METHODS

Experimental animals

Adult Swiss albino rats weighing 190–210 g were used in the present study. Animals were maintained under normal conditions and fed on a normal diet with free access to water *ad libitum*. Rats were randomly divided into four groups, six rats in each cage, as follows:

- Group I: The animals of this group were healthy normal rats and serves as untreated control group
- Group II-IV: On the basis of average consumption of food commodities and average level of detected colors, the animals of these groups were given blend of food colors at a dose of 25, 50 and 75 mg/kg body weight. The blend was prepared by mixing tartrazine, sunset yellow and metanil yellow in equal ratio and orally administered to experimental animals.

At the end of the experimental duration, the animals were weighed, anesthetized and sacrificed. The liver was removed and washed with cold normal saline and used to prepare liver homogenate.

Blood collection for the estimation of liver functions

Before sacrificing the animals, the blood was collected from retro-orbital plexus. The blood was incubated at 37°C for 10 min and centrifuged at 5000 rpm for 15 min. The resulting serum was used for analysis of total protein, albumin and ALP.

Assay of alkaline phosphatase, total protein and albumin

The levels of ALP, total protein and albumin in the serum of all rats were determined by the commercially available kits (Beacon laboratory kit). All analysis was performed according to the instructions of the manufacturer.

Liver homogenate preparation

The liver of different groups was dissected and rinsed thoroughly with ice-cold normal saline. It was smashed in a homogenization buffer and solution was sonicated in an ice bath for 30 s followed by centrifugation at 13000 rpm for 4 min at 4°C. The supernatant was stored at – 80°C and used for determination of the level of lipid peroxidation, the concentration of reduced GSH and the activities of SOD and CAT.

Assay of antioxidant markers of liver homogenate

Reduced glutathione

Reduced GSH was determined and the level of GSH is expressed as µg of GSH/mg protein.[4]

Assay of malondialdehyde

Lipid peroxidation was evaluated on the basis of MDA level and MDA in liver was determined.[5]

Assay of superoxide dismutase activity

SOD activity was determined by routine procedure and the activity of SOD was expressed as units/min/mg protein.[6]

Assay of catalase

CAT activity was determined by the earlier method reported and the activity was expressed as the amount of H₂O₂ utilized/min/mg protein.[7]

Histological examination

Liver tissues were collected after sacrificing the animals. Liver tissue was washed in normal saline and fixed in 10% neutral formalin and embedded in paraffin wax. Ten µm thick sections were prepared by rotary microtome and stained using H and E.[8]

Statistical analysis

All group values are expressed as a mean ± standard error of the mean. Statistical analysis was performed by one-way analysis of variance followed by Tukey's multiple comparison tests for comparison between different treatment groups. Statistical significance was set at $P < 0.05$.

RESULTS

Serum total protein, serum albumin and serum alkaline phosphatase level

Ingestion of food colors significantly increased total protein by 15%, albumin by 43.27% and ALP by 11.24% as compared with control rat (Group I). The oral ingestion of food color at the dose level of 50 mg/kg body weight and 75 mg/kg body weight further increased the level of total protein by 29.83% and 63.00%, albumin by 54.35% and 62.22% and ALP by 31.19% and 71.53% with respect to control animals [[Table 1](#)].

Figures [Figures 1–3](#) showed significant ($P < 0.001$) increase of total protein, albumin and ALP, respectively.

Tissue malondialdehyde levels

In the food color treated groups, a significant elevation was observed in tissue MDA content when compared with control group. The mean value of MDA content was recorded 3.45 ± 0.32 nmol/mg in control group [[Figure 4](#)] and it was increased by 31.30%, 63.19% and 118.26% in treated Groups II, III and IV, respectively [[Table 2](#)].

Tissue glutathione levels

In the food color treated groups, a significant depletion in the content of tissue GSH was recorded. The mean value of GSH was recorded 4.59 ± 0.13 μ g/mg in control group and 3.80 ± 0.13 , 2.96 ± 0.06 and 1.74 ± 0.18 μ g/mg in rats treated with increasing dose of food colors [[Table 2](#) and [Figure 5](#)].

Tissue superoxide dismutase levels

The activity of SOD in the tissue homogenates of all experimental rats was significantly decreased when compared with control [[Figure 6](#)]. In the liver homogenate, treatment of rat with 25, 50 and 75 mg/kg body weight food color caused a significant decrease by -23.48% , -43.01% and -58.03% respectively when compared with control group [[Table 2](#)].

Tissue catalase levels

As a result of food color administration, the activity of CAT was markedly reduced in comparison with control [[Figure 7](#)]. It was 5.10 ± 0.24 U/mg in control group while 3.91 ± 0.06 , 2.89 ± 0.20 and 1.99 ± 0.04 U/mg in respective treated Groups II, III and IV [[Table 2](#)].

Histological changes

The liver is the largest organ of the body and consists of numerous polyhedral hepatic lobules which are formed of a polygonal mass of tissue. Administration of food colors for 30 days caused huge changes in the liver. Necrosis and fibrosis were observed after treatment. After the treatment, hepatocytes were damaged and disrupted. There was pycnosis in liver nuclei [[Figure 8](#)].

DISCUSSION

The present study is concerned with the effect of blend of tartrazine, metanil yellow and sunset yellow on some biochemical parameters of Swiss albino rats.

The present study revealed a marked increase in serum protein, serum albumin and serum ALP at all dose levels of the blend of food colors. Tartrazine caused a highly significant increase in serum protein at a low dose and ALP at a low and high dose.[9] The high dose of tartrazine caused a significant increase in serum total protein and serum albumin.[10] The rats which consumed 7.5 and 10 mg/kg body weight of tartrazine showed a significant increase in serum total protein.[11] These results are in accordance with the present study. Our findings are also in agreement with the findings where rats treated with a higher dose of tartrazine showed an increase in total protein, albumin, and ALP.[12]

Food color may induce the oxidative stress in animal models leading to the generation of potent reactive oxygen species (ROS). Biological effect of ROS is controlled *in vivo* by wide spectrum of enzymatic and non-enzymatic defense mechanism, particularly by SOD which catalyzes dismutation of superoxide anions to hydrogen peroxide and CAT which then converts H₂O₂ into molecular oxygen and water.[13] SOD and CAT represents the front line of defense against oxidative damage. GSH is considered to be one of the most important component of the antioxidant defense of living cells. Lipid peroxidation is an autocatalytic free radical mediated destructive process, whereby polyunsaturated fatty acids in the cell membrane undergo degradation to form MDA.[14] MDA increase in rat liver is the indication of hepatotoxicity.

Hepatotoxicity not only initiates lipid peroxidation but also reduces the tissue GSH, CAT and SOD activities and this depletion may result from the oxidative stress of these proteins.[15,16,17,18] The current study is in agreement with these results which revealed that MDA was significantly higher in treated groups than the control group. In this study, significant decrease in SOD, GSH and CAT activities were observed in Group II, III and IV. MDA level was increased and GSH level was decreased with high tartrazine dose in liver homogenate which is in accordance with the present study.[19] When young male rats were given 500 mg/kg body weight dose of tartrazine, GSH level in tissue homogenate decreased significantly as compared to control.[10]

In the present study, food color caused hepatocellular necrosis and vacuolation and these results go in agreement with an earlier worker who found that the synthetic food dye brilliant blue revealed histopathological alteration in the liver of the rat.[20] This alteration includes necrosis of hepatocytes, infiltration and vacuolation. The food colors caused lymphocytic infiltration around central veins.[21] The hepatocellular necrosis in mice was observed when treated with commercial fruit drinks.[22] The present study is also in accordance with results where brown pigment deposition in the portal tract and Kupffer cells of the liver was observed.[23] Our results are also in accordance with the findings which described changes in the liver when guinea pigs received tartrazine in drinking water in a concentration of 1, 2 and 3% for 3 weeks.[24]

CONCLUSION

Our result indicates clearly that the daily intake of artificial food colorants that included the aromatic azo compounds impairs hepatic functions. The commodities consumed by children employ an excessive amount of colors as they attracted to colorful items so, excessive intake of food colorants may cause more risk to the health of children.

Financial support and sponsorship

Nil

Conflicts of interest

There are no conflicts of interest

Acknowledgment

The authors are grateful to the University Grant Commission, New Delhi for providing financial assistance to conduct this work.

REFERENCES

1. Dixit S, Purshottam SK, Khanna SK, Das M. Usage pattern of synthetic food colours in different states of India and exposure assessment through commodities preferentially consumed by children. *Food Addit Contam Part A Chem Anal Control Expo Risk Assess.* 2011;28:996–1005. [PubMed: 21790487]
2. El-Malky WA, Khiralla GM, Salem SA. Nutritional study of some coloring agents on experimental rats. *Int J Nutr Food Sci.* 2014;3:538–44.
3. Escobar JA, Rubio MA, Lissi EA. Sod and catalase inactivation by singlet oxygen and peroxy radicals. *Free Radic Biol Med.* 1996;20:285–90. [PubMed: 8720898]
4. Moron MS, Depierre JW, Mannervik B. Levels of glutathione, glutathione reductase and glutathione S-transferase activities in rat lung and liver. *Biochim Biophys Acta.* 1979;582:67–78. [PubMed: 760819]
5. Jain SK, McVie R, Duett J, Herbst JJ. Erythrocyte membrane lipid peroxidation and glycosylated hemoglobin in diabetes. *Diabetes.* 1989;38:1539–43. [PubMed: 2583378]
6. Marklund S, Marklund G. Involvement of the superoxide anion radical in the autooxidation of pyrogallol and convenient assay for superoxide dismutase. *J Biochem.* 1974;47:469–74.
7. Sinha AK. Colorimetric assay of catalase. *Anal Biochem.* 1972;47:389–94. [PubMed: 4556490]
8. Fukuzawa Y, Watanabe Y, Inaguma D, Hotta N. Evaluation of glomerular lesion and abnormal urinary findings in OLETF rats resulting from a long-term diabetic state. *J Lab Clin Med.* 1996;128:568–78. [PubMed: 8960640]
9. Sharma G, Gautam D, Goyal RP. Tartrazine induced haematological and serological changes in female Swiss albino mice, *Mus musculus*. *Pharmacologyonline.* 2009;3:774–88.
10. Amin KA, Abdel Hameid H, 2nd, Abd Elsttar AH. Effect of food azo dyes tartrazine and carmoisine on biochemical parameters related to renal, hepatic function and oxidative stress biomarkers in young male rats. *Food Chem Toxicol.* 2010;48:2994–9. [PubMed: 20678534]
11. Himri I, Bellahcen S, Souana F, Belmekki F, Aziz M, Bnouham M, et al. A 90 day oral toxicity study of tartrazine, a synthetic food dye, in wistar rats. *Int J Pharm Pharm Sci.* 2011;3:159–69.
12. Shinnawy MS, Elkattan N. Assessment of the changes in some diagnostic parameters in male albino rats fed on an azo dye. *Int J Environ Sci Eng.* 2013;4:85–92.

13. Inal ME, Kanbak G, Sunal E. Antioxidant enzyme activities and malondialdehyde levels related to aging. *Clin Chim Acta*. 2001;305:75–80. [PubMed: 11249925]
14. Zeyuan D, Binguin T, Xiaolin L, Yifeng C. Effect of green tea and black tea on the blood glucose, the blood triglycerides and antioxidant in aged rats. *J Agric Food Chem*. 1998;46:3875–8.
15. Augustyniak A, Waszkiewicz E, Skrzydlewska E. Preventive action of green tea from changes in the liver antioxidant abilities of different aged rats intoxicated with ethanol. *Nutrition*. 2005;21:925–32. [PubMed: 16084066]
16. Sayed AA, Morcos M. Thymoquinone decreases AGE-induced NF-kappaB activation in proximal tubular epithelial cells. *Phytother Res*. 2007;21:898–9. [PubMed: 17582594]
17. Lee KC, Chan CC, Yang YY, Hsieh YC, Huang YH, Lin HC. Aliskiren attenuates chronic carbon tetrachloride-induced liver injury in mice. *Eur J Clin Invest*. 2012;42:1261–71. [PubMed: 22998019]
18. Al-Malki AL, Sayed AA. Bees' honey attenuation of metanil-yellow-induced hepatotoxicity in rats. *Evid Based Complement Alternat Med*. 2013;2013:614580. [PMCID: PMC3684022] [PubMed: 23818929]
19. Cemek M, Buyukokuroglu ME, Sertkaya F, Alpdagtas S, Hazini A, Onul A. Effects of food color additive antioxidant functions and bioelement contents of liver, kidney and brain tissues in rats. *J Food Nutr Res*. 2014;2:686–91.
20. Mahmoud HN. Toxic effects of the synthetic food dye brilliant blue on liver, kidney and testes. *J Egypt Soc Toxicol*. 2006;34:77–84.
21. Soltan SA, Shehata MN. The effects of using color foods of children on immunity properties and liver, kidney on rats. *Food Nutr Sci*. 2012;3:897–904.
22. Eissa HA, Hassanane MM, Sharaf HA. Effect of colorant on cytogenetic, biochemical and histochemical parameters and quality changes during storage of some commercial fruit drinks. *J Nutr Food Sci*. 2014;4:1–11.
23. Aboel-Zahab H, el-Khyat Z, Sidhom G, Awadallah R, Abdel-al W, Mahdy K. Physiological effects of some synthetic food colouring additives on rats. *Boll Chim Farm*. 1997;136:615–27. [PubMed: 9528169]
24. Rus C, Gherman V, Miclaus A, Mihalca G, Nadas C. Comparative toxicity of food dyes on liver and kidney in Guinea pigs histopathological study. *Ann RSCB*. 2009;15:161–5.

Figures and Tables

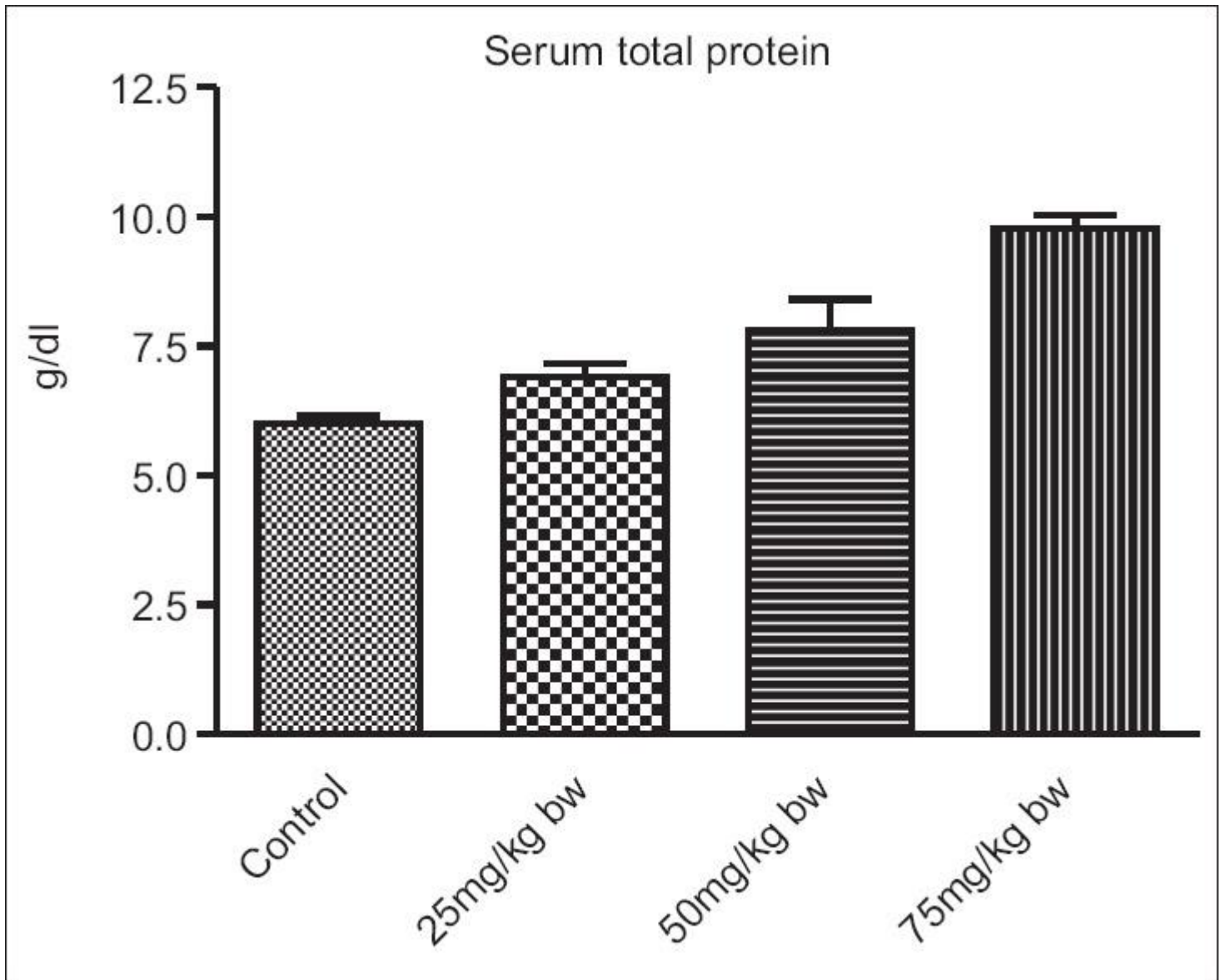
Table 1

Group	Total protein (g/dL)	Albumin (g/dL)	ALP (IU/L)
I	6.00±0.132	3.79±0.09	157.4±6.28
II	6.90±0.26 (+15.0) ²	5.43±0.02*** (+43.27) ²	175.10±7.46 (+11.24) ²
III	7.79±0.60* (+29.83) ²	5.85±0.17*** (+54.35) ²	206.5±1.56*** (+31.19) ²
IV	9.78±2.64*** (+63.00) ²	6.15±0.13*** (+62.22) ²	270.0±5.04*** (+71.53) ²

Each value is a mean±SEM for $n=6$. ^aValues in parentheses represents percent change with respect to control, * $P<0.05$, *** $P<0.001$. SEM = Standard error of mean, ALP = Alkaline phosphatase

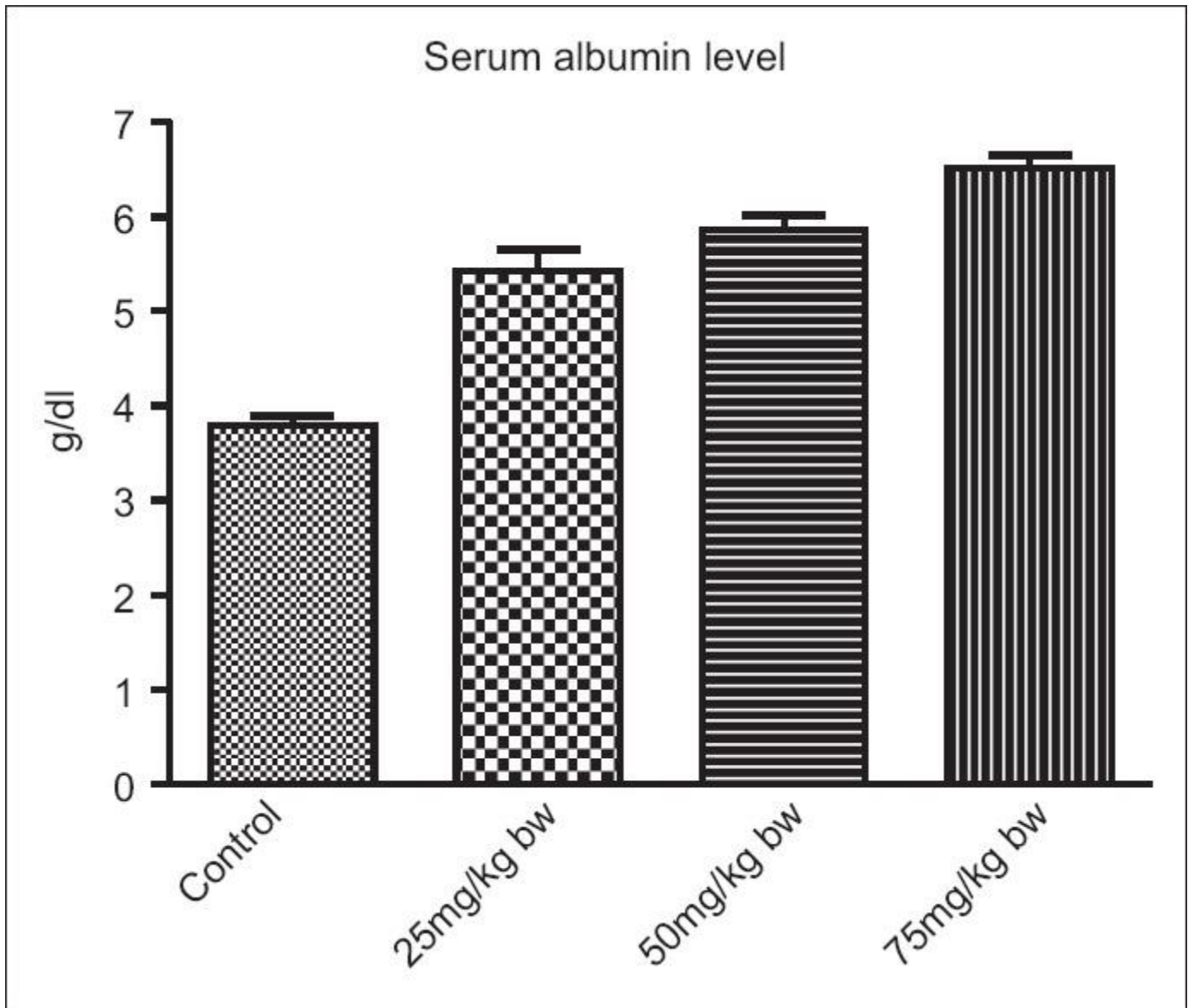
Effect of oral ingestion of blend of food colors at different dose level on serum protein, serum albumin and serum ALP in albino rats

Figure 1



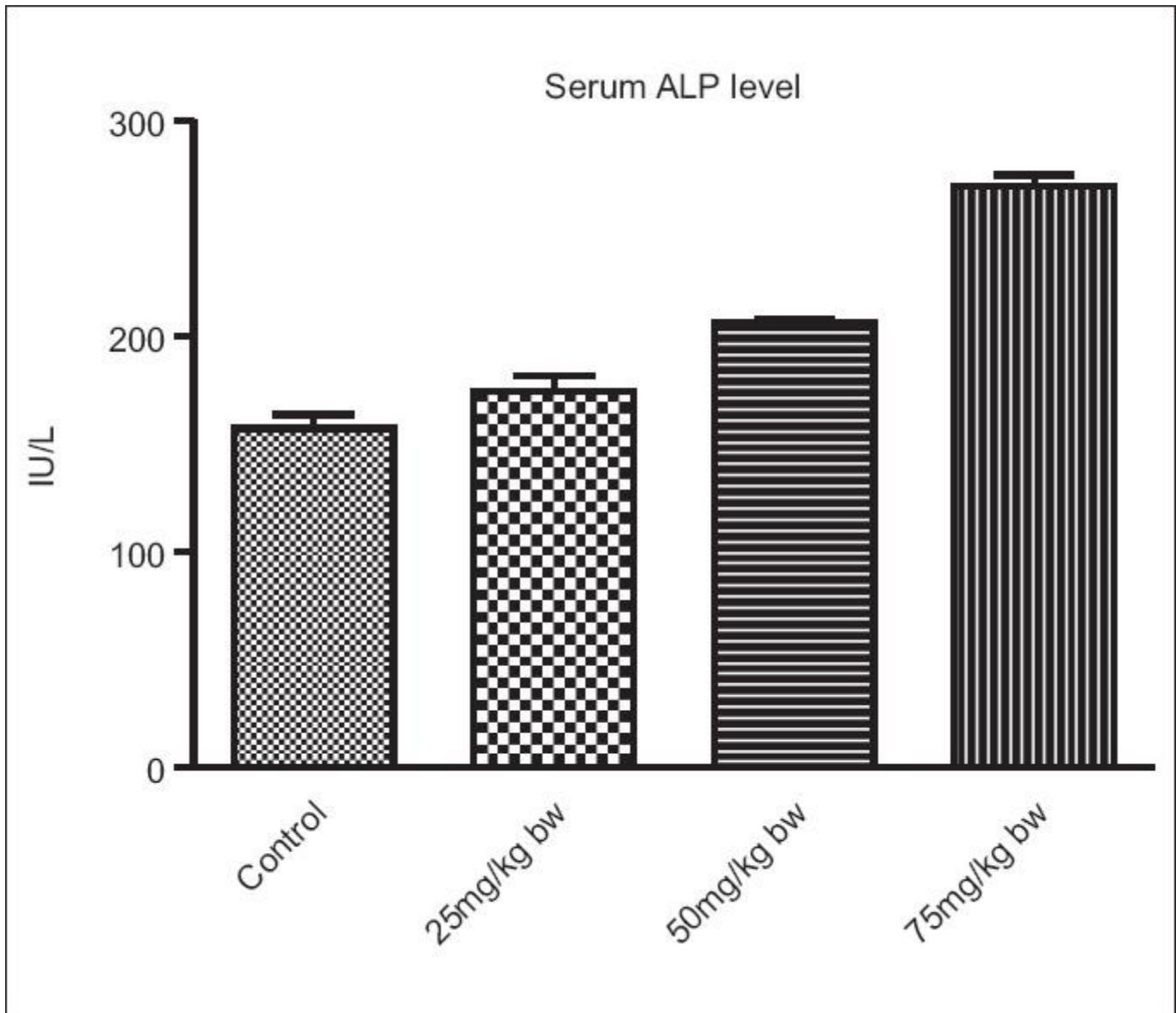
Effect of food colors on serum total protein

Figure 2



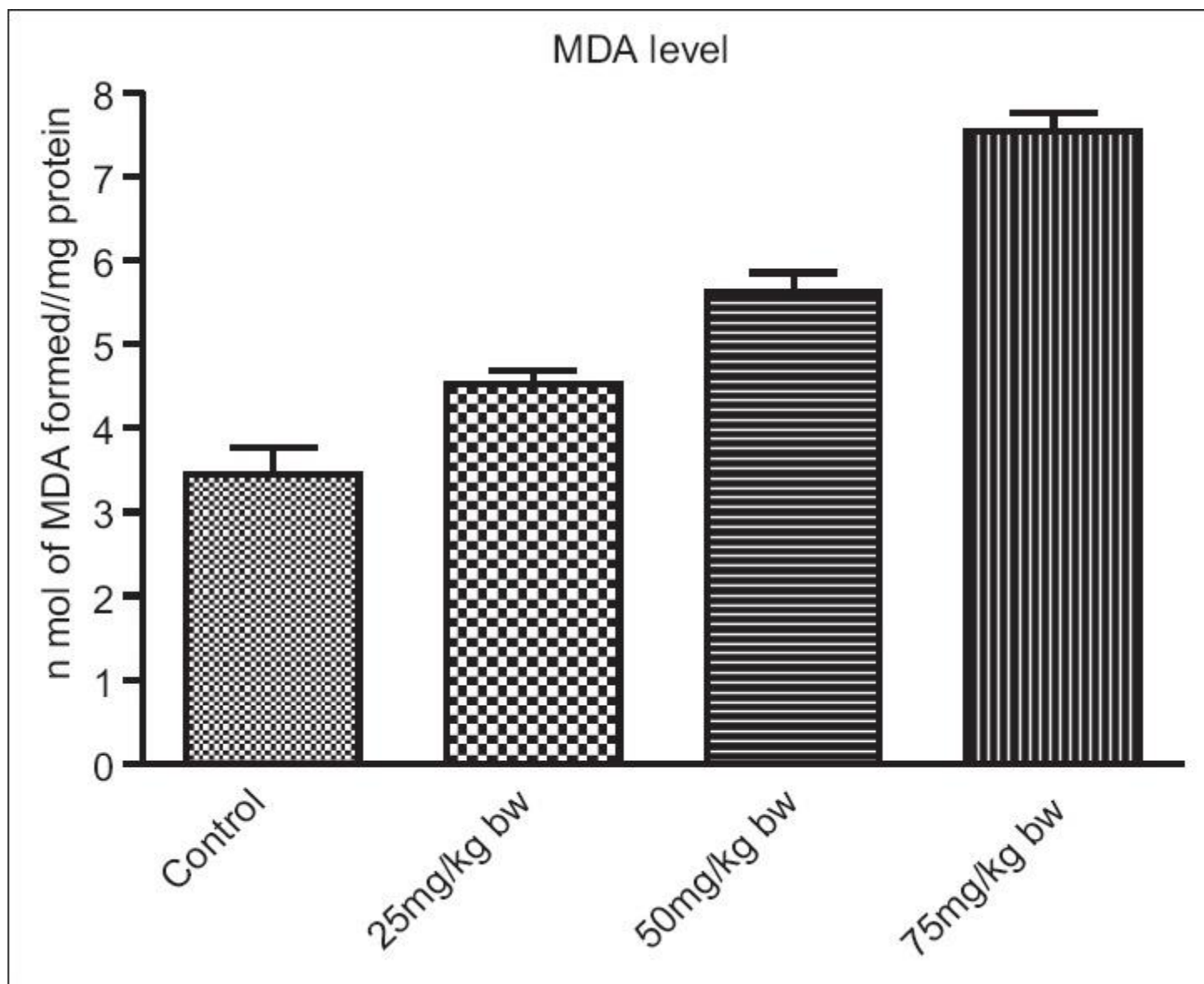
Effect of food colors on serum albumin level

Figure 3



Effect of food colors on serum alkaline phosphatase level

Figure 4



Effect of food colors on malondialdehyde concentration in liver tissue

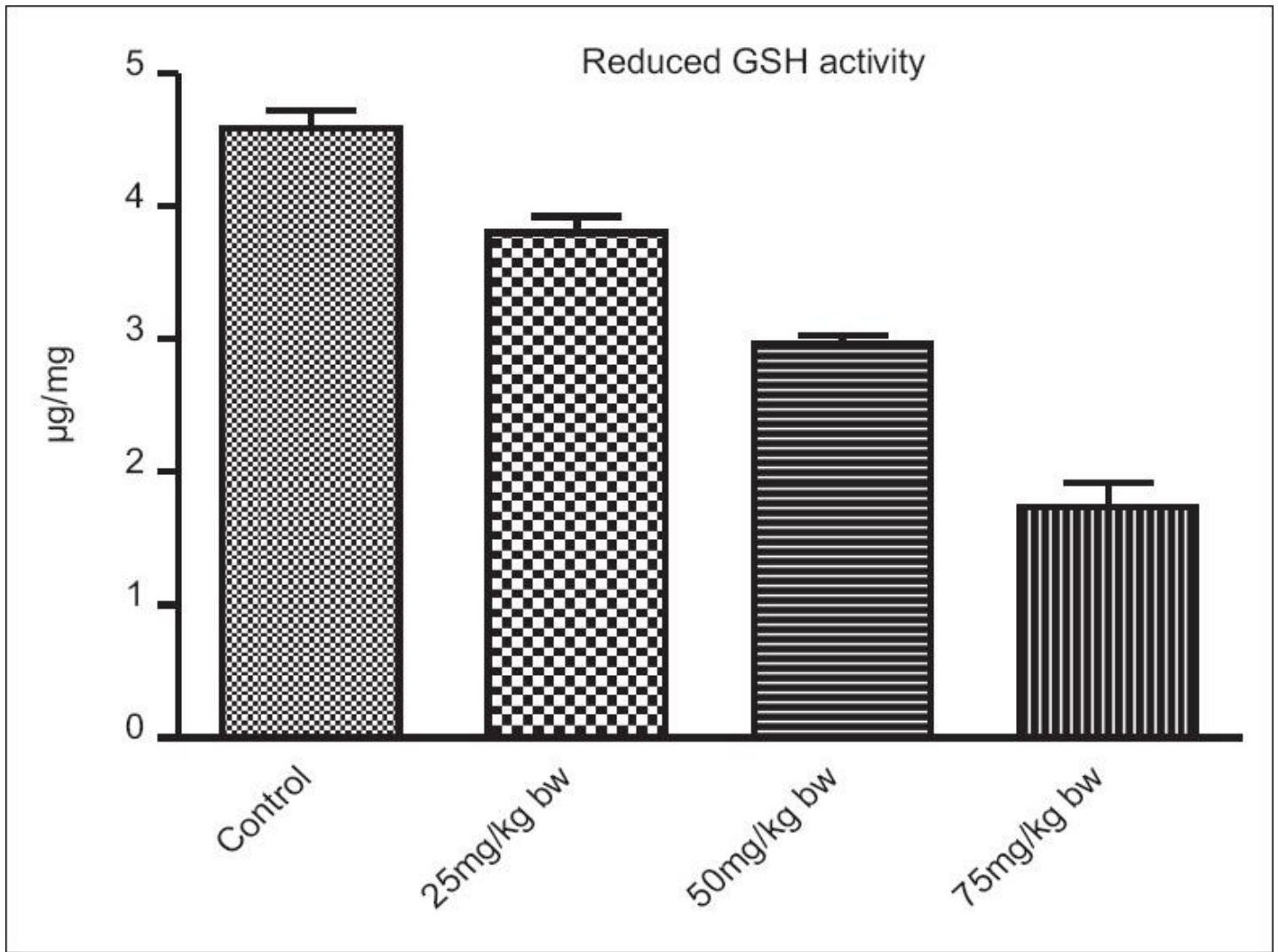
Table 2

Group	MDA nmol/min/mg	GSH μ g/mg protein	SOD units/min/mg protein	CAT H ₂ O ₂ utilised/min/mg protein
I	3.45±0.32	4.59±0.13	12.39±0.87	5.10±0.24
II	4.53±0.15* (+31.30) ^a	3.80±0.13** (-17.21) ^a	9.48±0.31** (-23.48) ^a	3.91±0.06*** (-23.33) ^a
III	5.63±0.22*** (+63.19) ^a	2.96±0.06*** (-35.51) ^a	7.06±0.37*** (-43.01) ^a	2.89±0.20*** (-43.33) ^a
IV	7.53±0.22*** (+118.26) ^a	1.74±0.18*** (-62.09) ^a	5.20±0.44*** (-58.03) ^a	1.99±0.04*** (-60.98) ^a

Each value is a mean±SEM for n=6. ^aValues in parentheses represents percent change with respect to control, *P<0.05, **P<0.01, ***P<0.001. SEM = Standard error of mean, SOD = Superoxide dismutase, CAT = Catalase, MDA = Malondialdehyde, GSH = Glutathione, ALP = Alkaline phosphatase

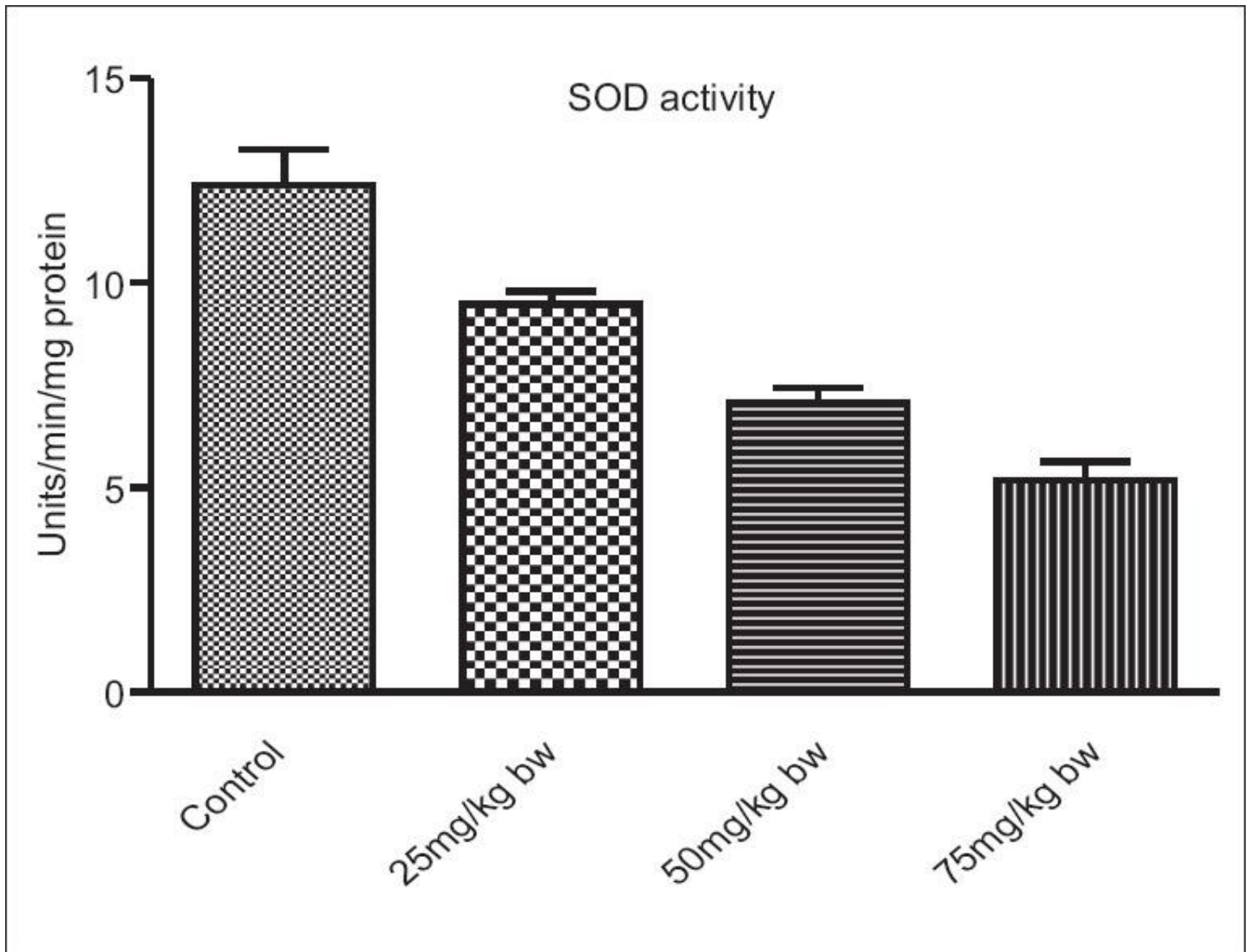
Effect of oral ingestion of blend of food colors at different dose level on oxidative stress parameters in liver of albino rats

Figure 5



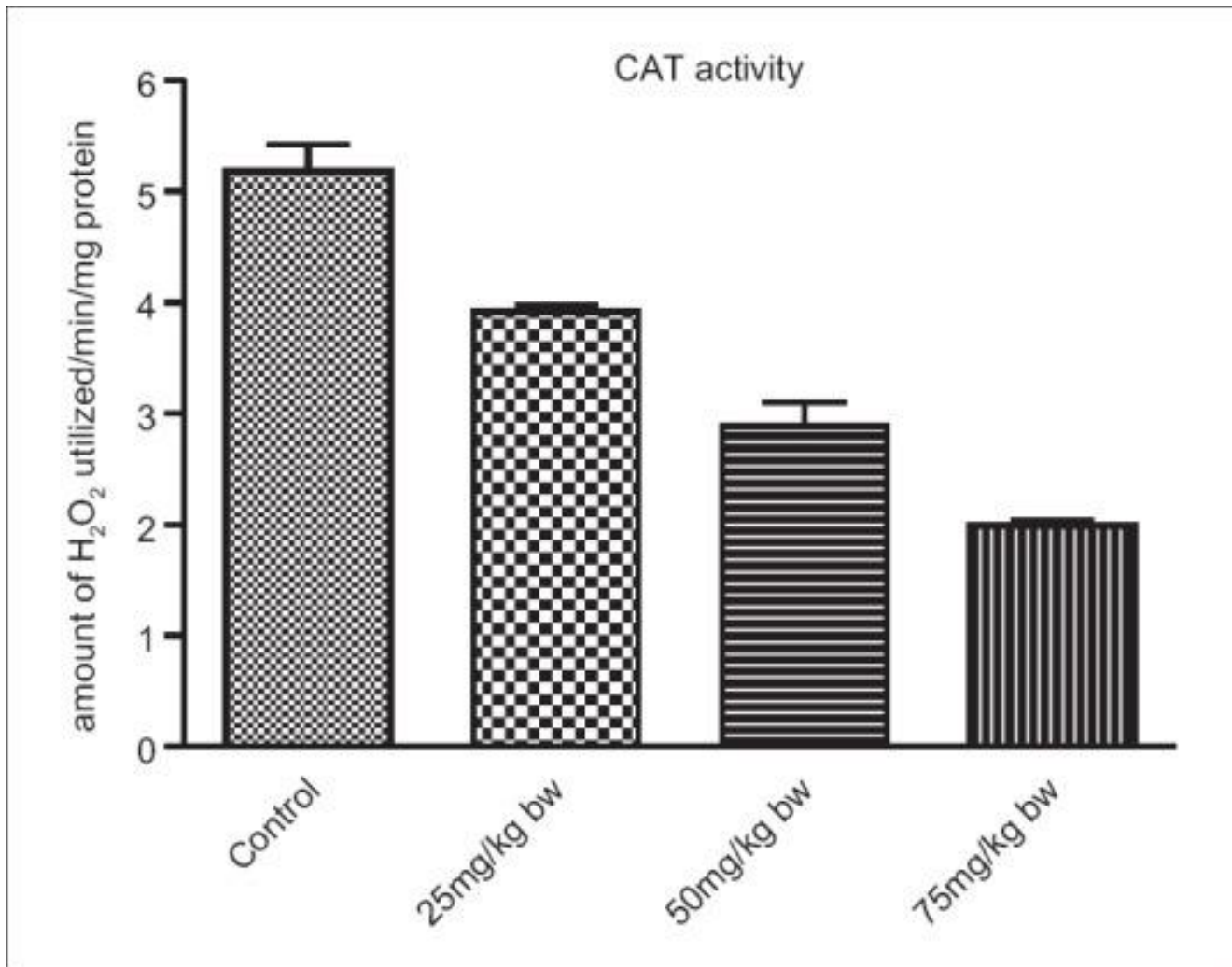
Effect of food colors on glutathione concentration in liver tissue

Figure 6



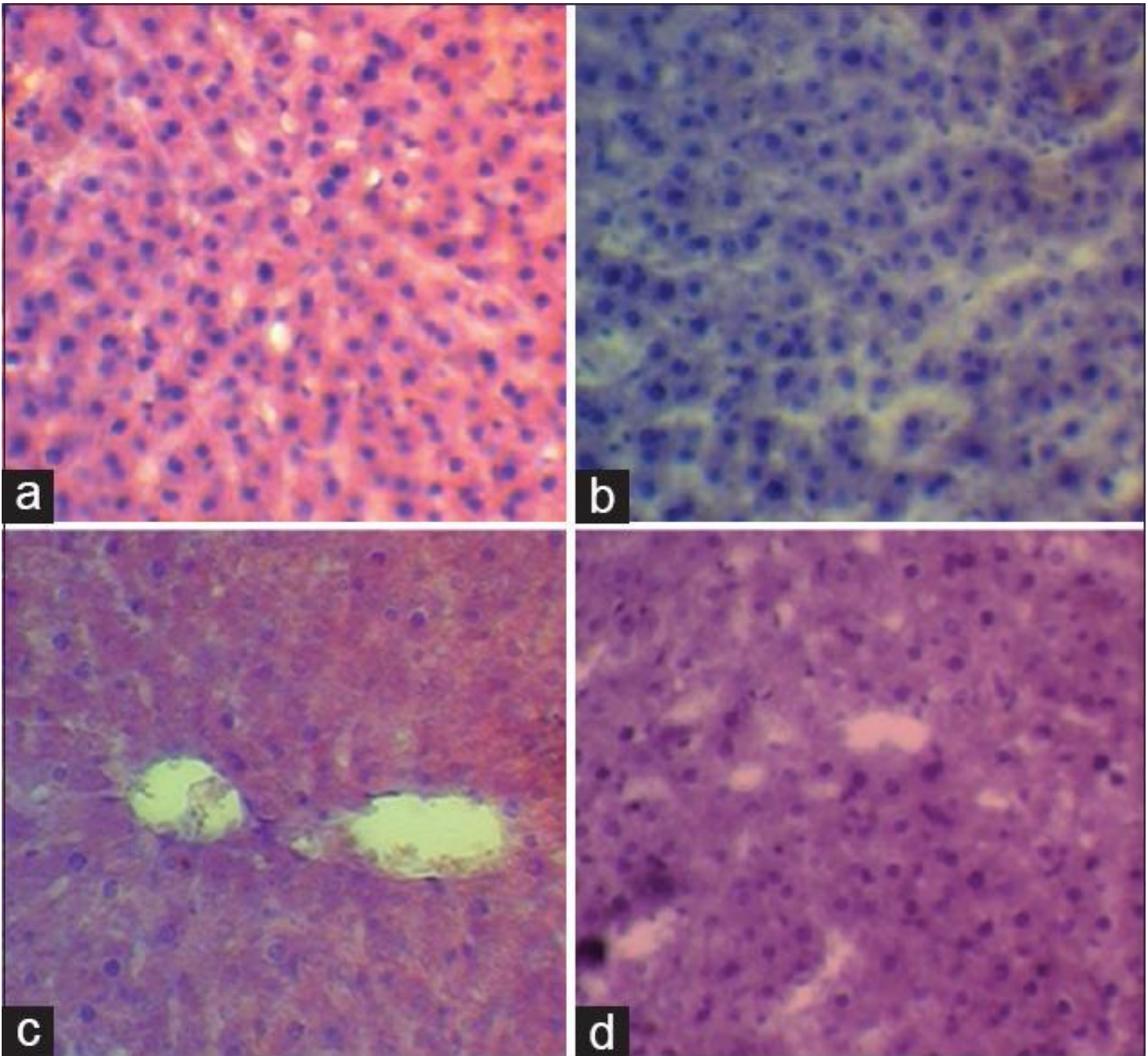
Effect of food colors on superoxide dismutase activity in liver tissue

Figure 7



Effect of food colors on catalase activity

Figure 8



Histological study of liver. (a) Liver section of control rat showing normal structures. (b) Liver section of rat at dose 25 mg/kg body weight for 30 days showing mucoid degeneration of hepatocyte. (c) Liver section of rat at dose 50 mg/kg body weight for 30 days showing degeneration and disruption of hepatocyte. (d) Liver section of rat at dose 75 mg/kg body weight for 30 days showing pyknotic nuclei and some vacuoles in hepatocyte